

# Liver Metastases

Roland Hustinx, MD, PhD<sup>a,\*</sup>, Nancy Witvrouw, MD<sup>a</sup>,  
Tino Tancredi, MD<sup>b</sup>

## KEYWORDS

- FDG • PET • PET/CT • Liver metastases
- Gastrointestinal cancers • MR imaging • CT

The liver is the most frequent site of hematogenous metastatic spread, and metastases represent the most frequent liver malignancy in the United States and Europe. Tumors of the gastrointestinal tract, in particular colorectal cancer, are the primary source of metastatic liver involvement but other tumors such as breast and lung cancers and melanomas also present a high likelihood of hepatic dissemination.<sup>1</sup> Close to 50% of the patients with colorectal cancer develop liver metastases, either at initial presentation or during the course of the disease, and the liver is the only site of distant spread in 30% to 50% of these patients. This represents a population that is likely to benefit from local therapy, in particular surgery. Indeed, surgical resection of liver metastases with curative intent can be performed with acceptable morbidity and leads to long-term survival rates of up to 58%. The classical criteria for selecting patients for surgery include the number and size of lesions as well as the necessity to achieve resection with a 1-cm free margin. In addition, the disease has typically to be limited to the liver. Recently, a trend has emerged to expand the inclusion criteria. This can be achieved through combining resection with radiofrequency ablation or neoadjuvant chemotherapy, which aims at reducing the tumor volume to be resected, or through portal vein embolization or two-stage hepatectomy, which aims at increasing the hepatic reserve. As thoroughly discussed in a recent review by Pawlik and colleagues,<sup>2</sup> a new paradigm consists of focusing the surgical decision on what would remain after resection, instead of what is to be removed. Basically, eligibility criteria

become all patients in whom all the lesions can be removed, including those outside of the liver, and in whom the hepatic reserve is adequate. Such approach obviously requires multidisciplinary and multimodality collaboration to appropriately select an ever-increasing number of patients. New treatment modalities also involve nuclear medicine physicians, with the development of techniques such as selective internal irradiation of glass or resin microspheres labeled with <sup>90</sup>Y.<sup>3,4</sup> Surgical resection of liver metastases from noncolorectal malignancies is also increasingly proposed, although with more limited clinical results and in a smaller number of patients.<sup>5</sup>

## CONVENTIONAL IMAGING MODALITIES

### *Ultrasonography*

Transabdominal ultrasonography (US) presents several advantages, including low cost, absence of irradiation, wide availability, and portability. The sensitivity is very low, however, as half of the lesions are missed and the specificity is not very high either.<sup>6</sup> More recently, developments in the technique such as Power Doppler or contrast enhancement with microbubbles have been reported to significantly improve the diagnostic accuracy, which may reach values close to those obtained with CT. For instance, a multicenter study was recently performed in 102 patients with various primaries.<sup>7</sup> Contrast-enhanced US (ceUS) identified 55 lesions classified as metastases, compared with 61 with triple-phase spiral CT and 53 with MR imaging. These results and others<sup>8,9</sup> are encouraging but it should be kept in mind that

<sup>a</sup> Division of Nuclear Medicine, University Hospital of Liège, Campus Universitaire du Sart Tilman B35, 4000 Liège, Belgium

<sup>b</sup> Department of Medical Imaging, University Hospital of Liège, Campus Universitaire du Sart Tilman B35, 4000 Liège, Belgium

\* Corresponding author.

E-mail address: rhustinx@chu.ulg.ac.be (R. Hustinx).

ceUS highly depends on the operator's skills and experience. Currently, US is not recommended as a screening or surveillance method for evaluating liver metastases.

### CT

CT technology has benefited from major technological improvements over the past decade. Multi-detector scanners allow very fast imaging, thus eliminating any respiratory artifacts and allowing precise timing of the various tissue enhancement after intravenous contrast injection, while achieving exquisite spatial resolution in all three planes. The CT appearance of liver metastases varies according to the pathologic type of the primary tumor. Metastases from melanomas, sarcomas, neuroendocrine tumors, and renal cell carcinomas are hypervascular and therefore better visualized during the hepatic arterial phase. Metastases from colorectal cancer are hypovascular and therefore better visualized during the portal venous phase.<sup>10</sup> Although breast cancer metastases may show early arterial enhancement, adding the early phase to the portal phase CT did not improve the sensitivity of the technique.<sup>11</sup> Therefore, triple-phase CT may not be mandatory in most patients being screened for liver metastases.

As may be expected and in spite of a very high spatial resolution, the detection rate of liver metastases by CT shows a negative correlation with the size of the lesions.<sup>12</sup> In lesion-per-lesion analyses, sensitivities ranging from 49% to 89% have been reported.<sup>12-14</sup> The specificity is usually high, although the study that showed the highest sensitivity (89%) also showed a rather poor specificity (67%).<sup>14</sup>

### MR Imaging

Similar to CT, MR imaging technology has witnessed important developments, in the hardware, image acquisition protocols, and contrast agents. On non-contrast-enhanced MR imaging, most metastases appear as hypo- to isointense on T1-weighted images and iso- to hyperintense on T2-weighted images.<sup>15</sup> Dynamic imaging after enhancement with gadolinium (Gd)-based agents provides information regarding the vascularity of the lesions and therefore increases the performance of MR imaging for differentiating benign from malignant lesions. Tissue-specific contrast agents have been introduced to increase the tumor-to-liver contrast. Mangafodipir trisodium (MnDPDP, Teslascan) is taken up by the hepatocytes, therefore increasing the signal from the normal liver on T1-weighted images. Superparamagnetic iron oxide (SPIO) is taken up by the

reticuloendothelial system (Kupffer cells in the liver) and causes a signal loss on T2-weighted images, therefore darkening the normal liver background on these images. Few systematic studies were performed comparing these tissue-specific contrast agents. In two Korean series from different investigators, the detection rate was similar for both mangafodipir and SPIO MR imaging.<sup>16,17</sup> MnDPDP-MR imaging appears to be more sensitive than both unenhanced MR imaging and spiral CT for detecting individual lesions.<sup>18</sup> Similarly, both Gd-enhanced and SPIO-enhanced MR imaging are more accurate than CT, and SPIO tends to perform better than Gd for detecting subcentimetric lesions.<sup>19</sup> Another series, however, reports similar results for CT and SPIO-enhanced MR imaging.<sup>14</sup> Currently, gadolinium remains the most widely used contrast agent when performing liver MR imaging in the clinical setting, but the precise clinical indication as well as the local experience of the radiology team contribute to guiding the choice of the technique, acquisition sequences, and contrast agent. In particular, MR imaging with liver-specific contrast agents is increasingly recommended in preoperative patients.<sup>20</sup>

### PET

Considering that 2-[<sup>18</sup>F]fluoro-2'-deoxyglucose (FDG) is avidly taken up by most cancer types and given the high prevalence of metastatic spread to the liver, it seems only logical to propose FDG-PET as a diagnostic and staging tool for liver involvement. The feasibility of the technique was suggested by Yonekura and colleagues<sup>21</sup> more than 25 years ago. Further studies, including those performed without attenuation correction, reported in the late 1990s diagnostic performances that compared favorably with the imaging methods routinely used at that time.<sup>22-25</sup> A first meta-analysis comparing US, CT, MR imaging, and PET for detecting liver metastases from cancers of the gastrointestinal tract was published in 2002.<sup>26</sup> The authors analyzed 54 studies, including 9 for US, 25 for CT, 11 for MR imaging, and 9 for PET. The most recent articles were published in 1996 for US and in 2000 for the other techniques. The total number of patients was 509 (US), 1371 (CT), 401 (MR imaging), and 423 (PET). The primaries were colorectal cancers in all cases for PET and MR imaging, and in 74% and 78% for US and CT, respectively. The other primaries were gastric or esophageal cancers. The prevalence of hepatic metastases in the population samples ranged from 33% (US studies) to 58% (PET studies). The mean weighted sensitivity was 66% for US, 70% for

CT, 71% for MR imaging, and 90% for PET. The authors further analyzed the data by stratifying subsets according to specificity. They considered that for any technique to be clinically useful and relevant, its specificity should be superior or equal to 85%. With such a cutoff for specificity, the sensitivity values became 55% for US, 72% for CT, 76% for MR imaging, and 90% for PET. The sensitivity was significantly higher for PET than for US and CT, and marginally higher when compared with MR imaging ( $P = .055$ ). There were statistically significant differences among the sensitivity of all three radiological techniques. Somewhat surprisingly, technical parameters did not influence the sensitivity of the various techniques. For instance, spiral CT did not perform any better than nonspiral CT, and SPIO-enhanced MR imaging was not more sensitive than unenhanced MR imaging. Equally troubling is the observation that in spite of a 15-year range of publication, the detection rate was not higher in the most recent studies, eg, reporting on the most recent technology.

Another meta-analysis was published more recently<sup>27</sup> Sixty-one studies published between January 1990 and December 2003 were included in this review. Only patients with colorectal cancer were considered, and US was not included in the analysis, owing to its well-known low sensitivity for detecting metastases on lesion-per-lesion basis. Overall, 2586 patients were studied with CT (621 with spiral CT), 564 patients with MR imaging (391 with 1.5-T systems), and 1058 with FDG-PET. According to the per-patient analysis, PET was significantly more sensitive (94.6%) than spiral CT (64.7%) and 1.5-T MR imaging (75.8%). The sensitivities for detecting individual lesions (per-lesion analysis) followed a similar pattern, with 63.8% for spiral CT, 64.4% for 1.5-T MR imaging, and 75.9% for FDG-PET. Further analyses showed that Gd and SPIO-enhanced MR imaging performed better than both unenhanced MR imaging and spiral CT with a low amount of contrast media. One limitation of this study is the lack of information regarding the specificity of the various imaging techniques.

Wiering and colleagues<sup>28</sup> further analyzed the performance of FDG-PET and evaluated its clinical impact in the management of colorectal liver metastases. The authors reviewed 32 articles and calculated the lesion-based sensitivity and specificity for detecting liver metastases. Overall, the pooled sensitivity was 88% for PET and 82.7% for CT, and the pooled specificity was 96.1% for PET and 84.1% for CT. When considering only the six studies with the highest methodological score, ie, with the strongest level of evidence, the sensitivity was a bit lower for PET (79.9%) but the specificity

remained very high, at 92.3%. CT had a sensitivity of 85.8% and a specificity of 88.3%. These results further illustrate that the diagnostic performances of PET and CT may be considered very similar for detecting individual liver lesions. Worth mentioning is the excellent specificity of PET, as most of the focal lesions that can be mistaken as metastases with CT, such as angiomas or adenomas, do not take up FDG. PET modified the clinical management in 30.8% of the patients in the studies that ranked above the mean regarding the methodological quality and in 25.4% of the patients when the evaluation was limited to the six highest-ranking publications. Most of the management changes came from the higher accuracy of PET for detecting extrahepatic disease. A recent prospective study conducted by the same group in 131 colorectal cancer patients who underwent surgery confirmed that the sensitivity of both PET and CT was a function of the lesions' size. Indeed, only 16% of the 63 metastases smaller than 1 cm were identified with both PET and CT, whereas CT and PET detected 72% and 75%, respectively, of the 123 lesions of 1 to 2 cm and almost all lesions larger than 2 cm were detected with both techniques.<sup>29</sup>

The clinical impact of PET was further emphasized in a series of 100 patients who underwent liver surgery with curative intent for metastatic spread from colorectal cancer.<sup>30</sup> These were preoperatively screened with FDG-PET, so that the operability criteria included the metabolic findings. The actuarial 5-year survival in this group was 58%, which is significantly higher than the 25% survival rate attained when conventional methods are used. In addition, preliminary data suggest that the metabolic activity of the liver metastases may predict the long-term outcome of patients who undergo curative surgery. In a homogeneous series of 90 patients, Riedl and colleagues<sup>31</sup> found that a higher standardized uptake value (SUV) was correlated with a shorter survival, as well as with biological markers such Ki67 and P53 expression.

### **PET/CT**

Despite excellent clinical results with FDG PET, the technique is intrinsically limited by the lack of precise and reliable anatomic information. Foci of increased uptake that are clearly located in the liver parenchyma are readily identified and usually correspond to metastases, but the bowel uptake is highly variable and may be focally increased in regions close to the liver, and therefore be mistaken with peripheral liver lesions. Combined PET/CT scanners allow the precise localization of the abnormal areas of uptake, and thus greatly increase the confidence with which the PET reports are

redacted and decreases the proportion of indeterminate or inconclusive findings.<sup>32</sup> Furthermore, modern PET/CT devices are equipped with high-end CT scanners, fully capable of performing full diagnostic CT studies. This raises several questions, such as, how does unenhanced PET/CT (PET/CT) perform compared with standalone PET and ceCT, should contrast-enhanced PET/CT (PET/ceCT) be the preferred modality for evaluating liver metastases, and which role remains for contrast-enhanced CT (ceCT) in the era of PET/CT? These questions are not fully answered yet, but enlightening data were recently published.

### **PET/CT versus PET, contrast-enhanced CT, and MR imaging**

Selzner and colleagues<sup>33</sup> studied 76 patients with liver metastases from colorectal cancer and who were considered for surgery. PET/CT and ceCT were performed within 2 weeks of each other, and results were compared with either surgical findings or clinical follow-up. Both techniques showed similar sensitivities for detecting liver metastases (95% for ceCT, 91% for PET/CT). Ten patients were free of malignant liver involvement. ceCT correctly identified 7 of 10 patients and PET/CT 9 of 10, the lone false-positive result corresponding to an abscess. Interestingly, PET/CT was more specific than ceCT for diagnosing intrahepatic recurrences in patients with prior hepatic resection (100% and 50%, respectively). This observation is clinically relevant, considering the increasing number of patients who undergo iterative liver surgery. The authors further confirmed the added value of PET/CT in detecting extrahepatic lesions, and found an overall positive impact of PET/CT on the clinical management in 21% of the cases. Rapoport and colleagues<sup>14</sup> systematically performed PET/CT, dual-phase ceCT and SPIO-MR imaging in 35 colorectal cancer patients, including 31 who underwent surgery. Both ceCT and MR imaging were significantly more sensitive than PET and PET/CT in a lesion-per-lesion analysis. In a patient-per-patient analysis, the sensitivity was 100% for ceCT, MR imaging, and PET/CT and 92% for PET, when the patients who had a recent chemotherapy were excluded. Indeed, it is well known that the sensitivity of FDG-PET is decreased by chemotherapy,<sup>33</sup> in particular, quite obviously, in patients who respond to the treatment.<sup>34</sup> Overall, the specificity was 99% for PET and PET/CT, 67% for ceCT and 81% for MR imaging.

In yet another effort to clarify the relative performances of all imaging modalities, Kong and colleagues<sup>35</sup> performed PET/CT, ceCT, and

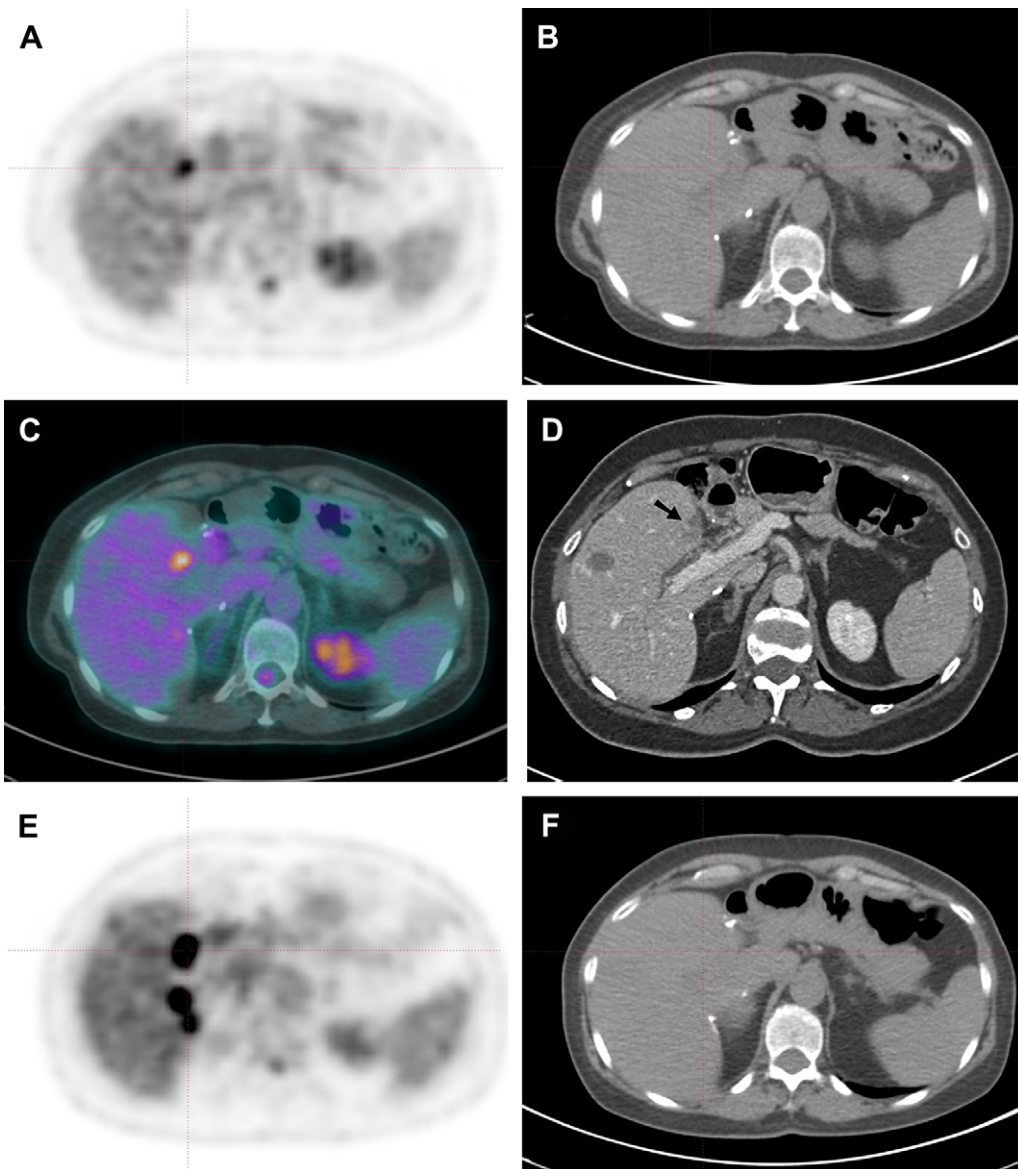
MnDPDP-MR imaging in 65 patients with colorectal cancer and known or suspected liver metastases. The gold standard was histopathology in 23 cases and a median clinical follow-up of 13 months in the remaining cases. According to the per-patient analysis, both PET/CT and MR imaging performed equally well, with a sensitivity of 98% and a specificity of 100%. The per-lesion analysis showed a slightly higher sensitivity with MR imaging (99%, 163 lesions detected) than with PET/CT (94%, 155 lesions). Almost all the lesions missed with PET/CT were smaller than 1 cm, which confirms the value of MR imaging for diagnosing small metastases. In 85% of the cases, both methods were concordant regarding the number of liver lesions that were detected. Although these authors compared PET/CT and MR imaging for liver imaging, they compared PET/CT and ceCT for the extrahepatic staging only. Chua et al,<sup>36</sup> however, evaluated PET/CT and ceCT in 131 patients with various malignancies, including 75 with colorectal cancer. All patients had either known or suspected liver involvement. The analysis was performed retrospectively and on a patient-per-patient basis, the gold standard being histology or a 6-month minimum follow-up. PET/CT and ceCT were in agreement in 75.5% of the patients (99 of 131). The sensitivity was 96% and 88%, and the specificity was 75% and 25% for PET/CT and ceCT, respectively. The specificity values must be read with caution, as only less than 10% of the population (12 of 131) was actually free of liver metastases. In addition, 15% of the patients were referred for evaluating indeterminate findings on CT, which may further contribute decreasing the specificity of ceCT. Nonetheless, these results confirm the very high sensitivity of PET/CT for detecting liver metastases, including those arising from noncolorectal tumors. Typical FDG PET/CT studies are shown in **Figs. 1 and 2**.

### **Diagnostic Algorithms**

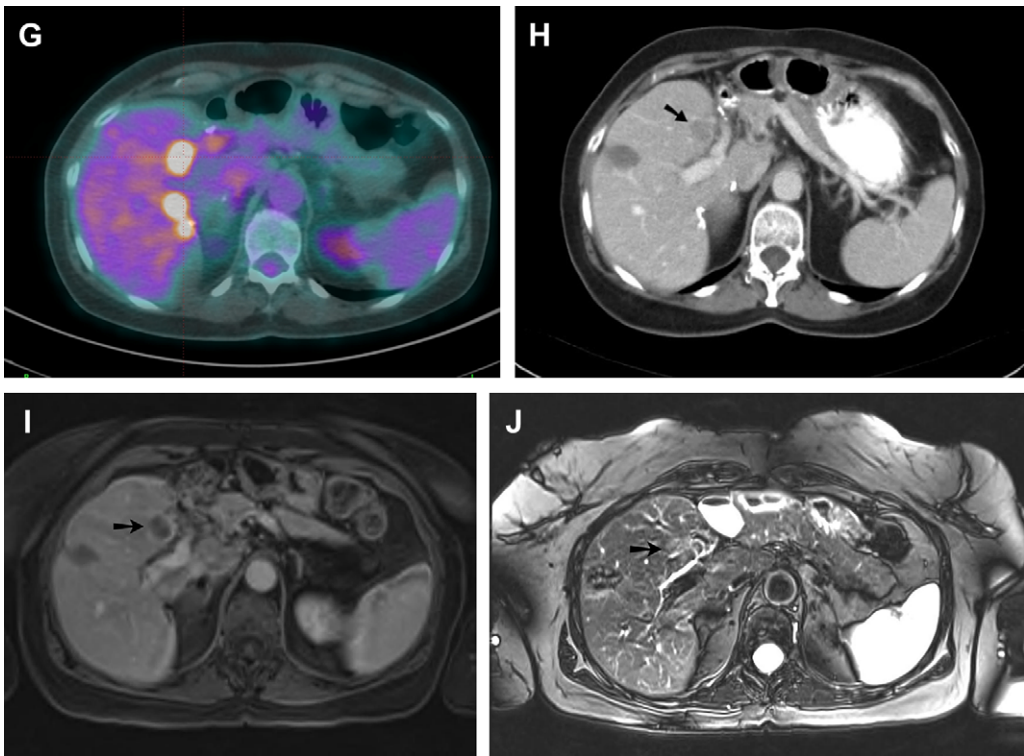
It clearly appears that a single imaging modality cannot be proposed to answer all the clinical questions that may arise in all patients. The choice among the various techniques, and the sequence with which they are used, should be guided primarily by the clinical indication, taking into account the primary type and the different possible treatments, which also depend on the general status of clinical history of the patient. Nevertheless, according to the results presented in the previous section, it becomes increasingly difficult to defend the role of ceCT in the evaluation of liver metastases. All the available data yield similar conclusions,

ie, a sensitivity that is comparable or higher and a specificity that is consistently higher with PET/CT than with ceCT. A positive clinical impact of PET/CT is reported in about 20% to 25% of the cases, primarily by detecting extrahepatic lesions,<sup>33,35</sup> but also by detecting additional liver lesions or even by ruling out liver metastases.<sup>36</sup> On the other hand, Soyka and colleagues<sup>37</sup> recently reported additional information revealed

by PET/ceCT as compared with PET/CT in 39 (72%) of 52 patients with recurrent colorectal cancer. This additional information altered the therapeutic management in 23 cases. However, most of these changes came from a proper segmental localization of the liver lesions, which is mandatory before surgery and cannot be reliably provided without intravenous (IV) contrast. As PET/CT, as a whole-body imaging method, is highly accurate



**Fig. 1.** A 60-year-old woman with a previous history of colon cancer with resected liver metastasis is explored for an increase in CEA levels. The PET/CT shows a small focus of increased activity in the segment IV of the liver (A, PET; B, low-dose, unenhanced CT; C, fused images). The contrast-enhanced CT shows a small lesion, which was already seen on previous CT studies and appears to be stable (D, portal phase). The MR imaging is negative. It is thus decided to follow the patients. A repeat PET/CT is performed 4 months later showing a progression of the lesions as well as additional liver metastases (E–G). At that time, CeCT and MR imaging confirm the metastatic progression (H, portal-phase CT; I, Gd-enhanced T1-weighted MR; J, T2-weighted MR).



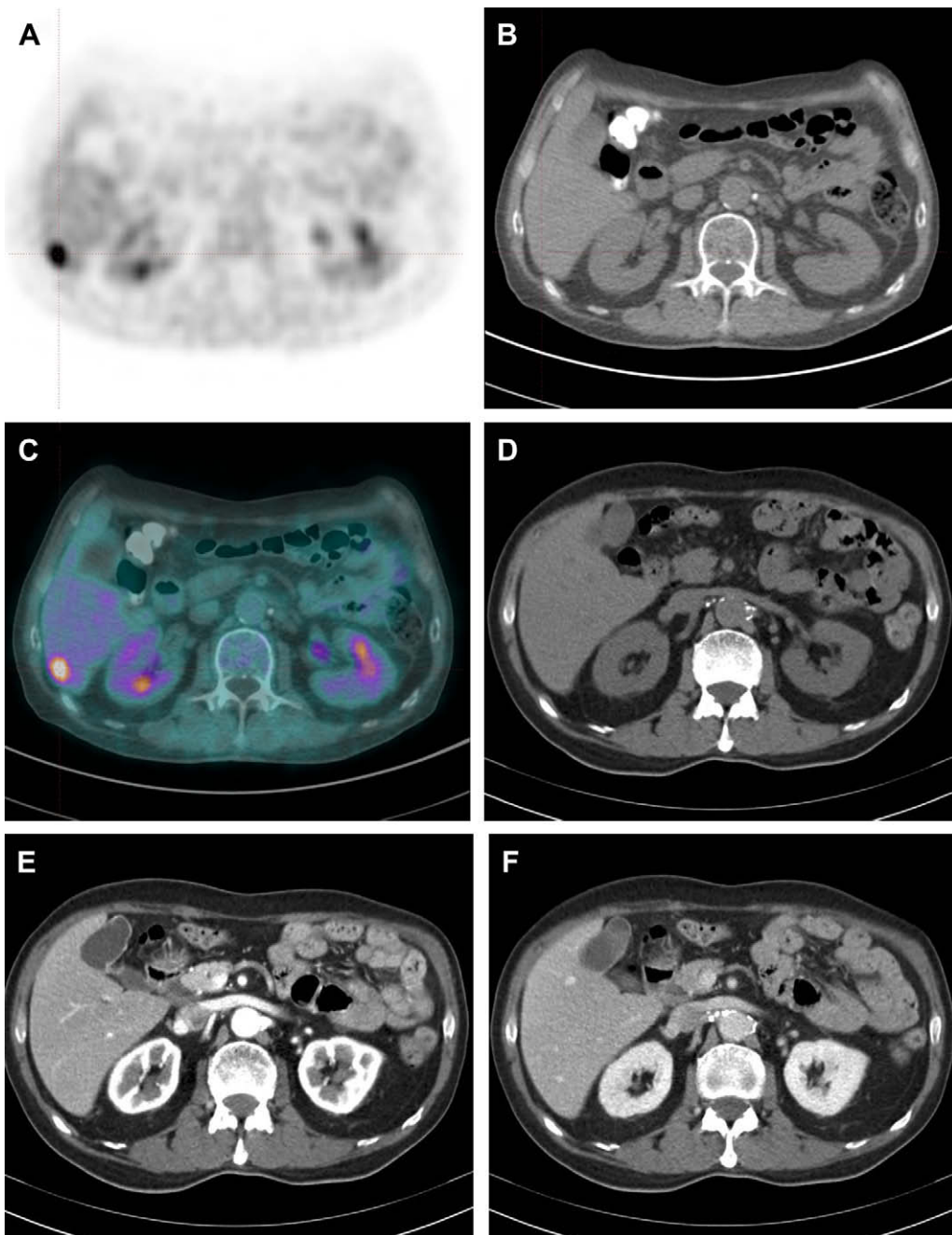
**Fig. 1.** (continued)

for both the liver and other possible locations of metastatic spread, it seems fairly logical to propose this technique relatively early on in patients who should be selected for a high likelihood of disease, based on clinical criteria. Dedicated liver imaging is not needed in patients diagnosed at PET/CT with disseminated, inoperable disease, whereas both ceCT and MR imaging with tissue-specific contrast agents should complement the preoperative local staging. Cost and availability have often been put forward to prevent PET and PET/CT from being used as a first-line tool. However, cost has significantly decreased and availability, increased, over the past 10 years. Modern scanners are much faster, allowing high throughput while maintaining the radiation burden to the patients within reasonable limits. Of course, this potential algorithm must be appropriately tested and validated, but the matter of the fact is currently that ceCT adds very little, if any, to PET/CT in most patients who are explored for possible liver metastases.

#### **PET/CT and Locoregional Treatment of Liver Metastases**

As mentioned earlier, a variety of local ablative therapies are available and may be performed

when surgery is contraindicated. These techniques include radiofrequency ablation (RFA), which is the best known, interstitial laser therapy, and microwave ablation. PET/CT has been evaluated in the preinterventional setting, with results very similar to ceCT,<sup>38</sup> but its real value probably lies in the follow-up of patients who underwent such procedure. Several retrospective studies showed, in a limited number of patients, a high accuracy for PET in detecting residual of recurrent lesions after RFA.<sup>39,40</sup> Travaini and colleagues<sup>41</sup> performed in a series of nine patients, both PET/CT and ceCT at 1, 3, 6, and 9 months after RFA. In 7 of 9 patients, PET/CT was positive earlier than ceCT, 3 months on average, for detecting evolutive disease. Kuehl and colleagues<sup>42</sup> showed very similar diagnostic performances for both PET/ceCT and Gd-enhanced MR imaging in 16 patients with metastases from colorectal cancer, with an accuracy of 92% and 91%, respectively. PET/CT was performed as early as 24 hours after ablation. The technique may therefore be proposed as a first-line tool in the follow-up of these patients, provided that the lesions were initially FDG-avid and no adjuvant chemotherapy is administered. Whenever this is the case, MR imaging is the modality of choice.



**Fig. 2.** A 75-year-old man is referred before surgical resection of a rectal cancer. PET/CT shows a liver metastasis in the segment of the liver (A, PET; B, low-dose, unenhanced CT; C, fused images). Diagnostic CT is negative (D, unenhanced; E, arterial phase; F, portal phase).

FDG-PET is also able to evaluate the metabolic response after intraarterial  $^{90}\text{Y}$ -microsphere treatment of liver metastases.<sup>4,43</sup> However, only preliminary data are available and the technique requires further validation before it could be routinely proposed.

#### SUMMARY

FDG PET/CT has strongly established its high diagnostic accuracy for diagnosing liver metastases from colorectal cancers as well as from most malignant tumors. The vast majority of the patients are accurately staged with PET/CT, without the

need for contrast-enhanced CT. PET/CT has limitations, especially for detecting very small lesions, which are better visualized with MR imaging, although the specificity of MR imaging may be an issue. The optimal preoperative liver staging probably combines MR imaging with PET/CT; in this case with IV contrast enhancement to precisely define the segmental localization of the lesions. PET/CT has a significant positive impact on the management of patients, thanks to a high accuracy both inside and outside the liver. The results are encouraging in patients treated with locoregional approaches, although further validation is needed.

## REFERENCES

- Bhattacharya R, Rao S, Kowdley KV. Liver involvement in patients with solid tumors of nonhepatic origin. *Clin Liver Dis* 2002;6(4):1033–43, x.
- Pawlik TM, Schulick RD, Choti MA. Expanding criteria for resectability of colorectal liver metastases. *Oncologist* 2008;13(1):51–64.
- Lim L, Gibbs P, Yip D, et al. A prospective evaluation of treatment with Selective Internal Radiation Therapy (SIR-spheres) in patients with unresectable liver metastases from colorectal cancer previously treated with 5-FU based chemotherapy. *BMC Cancer* 2005;5:132.
- Lewandowski RJ, Thurston KG, Goin JE, et al. 90Y microsphere (TheraSphere) treatment for unresectable colorectal cancer metastases of the liver: response to treatment at targeted doses of 135–150 Gy as measured by [18F]fluorodeoxyglucose positron emission tomography and computed tomographic imaging. *J Vasc Interv Radiol* 2005;16(12):1641–51.
- Kuvshinoff B, Fong Y. Surgical therapy of liver metastases. *Semin Oncol* 2007;34(3):177–85.
- Choi J. Imaging of hepatic metastases. *Cancer Control* 2006;13(1):6–12.
- Dietrich CF, Kratzer W, Strobe D, et al. Assessment of metastatic liver disease in patients with primary extrahepatic tumors by contrast-enhanced sonography versus CT and MRI. *World J Gastroenterol* 2006;12(11):1699–705.
- Albrecht T, Blomley MJ, Burns PN, et al. Improved detection of hepatic metastases with pulse-inversion US during the liver-specific phase of SHU 508A: multicenter study. *Radiology* 2003;227(2):361–70.
- Albrecht T, Hoffmann CW, Schmitz SA, et al. Phase-inversion sonography during the liver-specific late phase of contrast enhancement: improved detection of liver metastases. *AJR Am J Roentgenol* 2001;176(5):1191–8.
- Soyer P, Pocard M, Boudiaf M, et al. Detection of hypovascular hepatic metastases at triple-phase helical CT: sensitivity of phases and comparison with surgical and histopathologic findings. *Radiology* 2004;231(2):413–20.
- Sheafor DH, Frederick MG, Paulson EK, et al. Comparison of unenhanced, hepatic arterial-dominant, and portal venous-dominant phase helical CT for the detection of liver metastases in women with breast carcinoma. *AJR Am J Roentgenol* 1999;172(4):961–8.
- van Erkel AR, Pijl ME, van den Berg-Huysmans AA, et al. Hepatic metastases in patients with colorectal cancer: relationship between size of metastases, standard of reference, and detection rates. *Radiology* 2002;224(2):404–9.
- Kamel IR, Georgiades C, Fishman EK. Incremental value of advanced image processing of multislice computed tomography data in the evaluation of hypervascular liver lesions. *J Comput Assist Tomogr* 2003;27(4):652–6.
- Rappeport ED, Loft A, Berthelsen AK, et al. Contrast-enhanced FDG-PET/CT vs. SPIO-enhanced MRI vs. FDG-PET vs. CT in patients with liver metastases from colorectal cancer: a prospective study with intraoperative confirmation. *Acta Radiol* 2007;48(4):369–78.
- Namasivayam S, Martin DR, Saini S. Imaging of liver metastases: MRI. *Cancer Imaging* 2007;7:2–9.
- Kim HJ, Kim KW, Byun JH, et al. Comparison of mangafodipir trisodium- and ferucarbotran-enhanced MRI for detection and characterization of hepatic metastases in colorectal cancer patients. *AJR Am J Roentgenol* 2006;186(4):1059–66.
- Choi JY, Kim MJ, Kim JH, et al. Detection of hepatic metastasis: manganese- and ferucarbotran-enhanced MR imaging. *Eur J Radiol* 2006;60(1):84–90.
- Bartolozzi C, Donati F, Cioni D, et al. Detection of colorectal liver metastases: a prospective multicenter trial comparing unenhanced MRI, MnDPDP-enhanced MRI, and spiral CT. *Eur Radiol* 2004;14(1):14–20.
- Ward J, Robinson PJ, Guthrie JA, et al. Liver metastases in candidates for hepatic resection: comparison of helical CT and gadolinium- and SPIO-enhanced MR imaging. *Radiology* 2005;237(1):170–80.
- Schima W, Kulinna C, Langenberger H, et al. Liver metastases of colorectal cancer: US, CT or MR? *Cancer Imaging* 2005;5(Spec No A):S149–56.
- Yonekura Y, Benua RS, Brill AB, et al. Increased accumulation of 2-deoxy-2-[18F]Fluoro-D-glucose in liver metastases from colon carcinoma. *J Nucl Med* 1982;23(12):1133–7.
- Delbeke D, Martin WH, Sandler MP, et al. Evaluation of benign vs malignant hepatic lesions with positron emission tomography. *Arch Surg* 1998;133(5):510–5 [discussion: 5–6].
- Hustinx R, Paulus P, Jacquet N, et al. Clinical evaluation of whole-body 18F-fluorodeoxyglucose



- positron emission tomography in the detection of liver metastases. *Ann Oncol* 1998;9(4):397–401.
24. Lai DT, Fulham M, Stephen MS, et al. The role of whole-body positron emission tomography with [18F]fluorodeoxyglucose in identifying operable colorectal cancer metastases to the liver. *Arch Surg* 1996;131(7):703–7.
  25. Vitola JV, Delbeke D, Sandler MP, et al. Positron emission tomography to stage suspected metastatic colorectal carcinoma to the liver. *Am J Surg* 1996; 171(1):21–6.
  26. Kinkel K, Lu Y, Both M, et al. Detection of hepatic metastases from cancers of the gastrointestinal tract by using noninvasive imaging methods (US, CT, MR imaging, PET): a meta-analysis. *Radiology* 2002; 224(3):748–56.
  27. Bipat S, van Leeuwen MS, Comans EF, et al. Colorectal liver metastases: CT, MR imaging, and PET for diagnosis—meta-analysis. *Radiology* 2005; 237(1):123–31.
  28. Wiering B, Krabbe PF, Jager GJ, et al. The impact of fluor-18-deoxyglucose-positron emission tomography in the management of colorectal liver metastases. *Cancer* 2005;104(12):2658–70.
  29. Wiering B, Ruers TJ, Krabbe PF, et al. Comparison of multiphase CT, FDG-PET and intra-operative ultrasound in patients with colorectal liver metastases selected for surgery. *Ann Surg Oncol* 2007;14(2): 818–26.
  30. Fernandez FG, Drebin JA, Linehan DC, et al. Five-year survival after resection of hepatic metastases from colorectal cancer in patients screened by positron emission tomography with F-18 fluorodeoxyglucose (FDG-PET). *Ann Surg* 2004;240(3):438–47 [discussion: 47–50].
  31. Riedl CC, Akhurst T, Larson S, et al. 18F-FDG PET scanning correlates with tissue markers of poor prognosis and predicts mortality for patients after liver resection for colorectal metastases. *J Nucl Med* 2007;48(5):771–5.
  32. Cohade C, Osman M, Leal J, et al. Direct comparison of (18)F-FDG PET and PET/CT in patients with colorectal carcinoma. *J Nucl Med* 2003;44(11): 1797–803.
  33. Selzner M, Hany TF, Wildbrett P, et al. Does the novel PET/CT imaging modality impact on the treatment of patients with metastatic colorectal cancer of the liver? *Ann Surg* 2004;240(6):1027–34 [discussion: 35–6].
  34. Lubezky N, Metser U, Geva R, et al. The role and limitations of 18-fluoro-2-deoxy-D-glucose positron emission tomography (FDG-PET) scan and computerized tomography (CT) in restaging patients with hepatic colorectal metastases following neoadjuvant chemotherapy: comparison with operative and pathological findings. *J Gastrointest Surg* 2007;11(4): 472–8.
  35. Kong G, Jackson C, Koh DM, et al. The use of (18) F-FDG PET/CT in colorectal liver metastases—comparison with CT and liver MRI. *Eur J Nucl Med Mol Imaging* 2008;35(7):1323–9.
  36. Chua SC, Groves AM, Kayani I, et al. The impact of 18F-FDG PET/CT in patients with liver metastases. *Eur J Nucl Med Mol Imaging* 2007;34(12):1906–14.
  37. Soyka JD, Veit-Haibach P, Strobel K, et al. Staging pathways in recurrent colorectal carcinoma: is contrast-enhanced 18F-FDG PET/CT the diagnostic tool of choice? *J Nucl Med* 2008;49(3):354–61.
  38. Kuehl H, Rosenbaum-Krumme S, Veit-Haibach P, et al. Impact of whole-body imaging on treatment decision to radio-frequency ablation in patients with malignant liver tumors: comparison of [18F]fluorodeoxyglucose-PET/computed tomography, PET and computed tomography. *Nucl Med Commun* 2008;29(7):599–606.
  39. Veit P, Antoch G, Stergar H, et al. Detection of residual tumor after radiofrequency ablation of liver metastasis with dual-modality PET/CT: initial results. *Eur Radiol* 2006;16(1):80–7.
  40. Anderson GS, Brinkmann F, Soulen MC, et al. FDG positron emission tomography in the surveillance of hepatic tumors treated with radiofrequency ablation. *Clin Nucl Med* 2003;28(3):192–7.
  41. Travaini LL, Trifiro G, Ravasi L, et al. Role of [(18)F]FDG-PET/CT after radiofrequency ablation of liver metastases: preliminary results. *Eur J Nucl Med Mol Imaging* 2008;35(7):1316–22.
  42. Kuehl H, Antoch G, Stergar H, et al. Comparison of FDG-PET, PET/CT and MRI for follow-up of colorectal liver metastases treated with radiofrequency ablation: initial results. *Eur J Radiol* 2008;67(2): 362–71.
  43. Wong CY, Salem R, Qing F, et al. Metabolic response after intraarterial 90Y-glass microsphere treatment for colorectal liver metastases: comparison of quantitative and visual analyses by 18F-FDG PET. *J Nucl Med* 2004;45(11):1892–7.