



**EMORY**  
UNIVERSITY  
SCHOOL OF  
MEDICINE

**Department of  
Pathology and  
Laboratory  
Medicine**



Georgia Association of Pathology

EMORY

.....

# 2020 Virtual Pathology Course

**FAISAL SAEED, MD**

**GENITOURINARY  
PATHOLOGIST**

**ASSISTANT PROFESSOR**

# Faisal Saeed, MD

## Disclosures

---

None.

## Academic Background

Residency: New York Medical College (2014-2018)

Fellowship: Surgical Pathology at Emory University (2018-2019)

Clinical Instructor: Emory University (2019-2020)

Assistant Professor: Emory University (2020-Present)

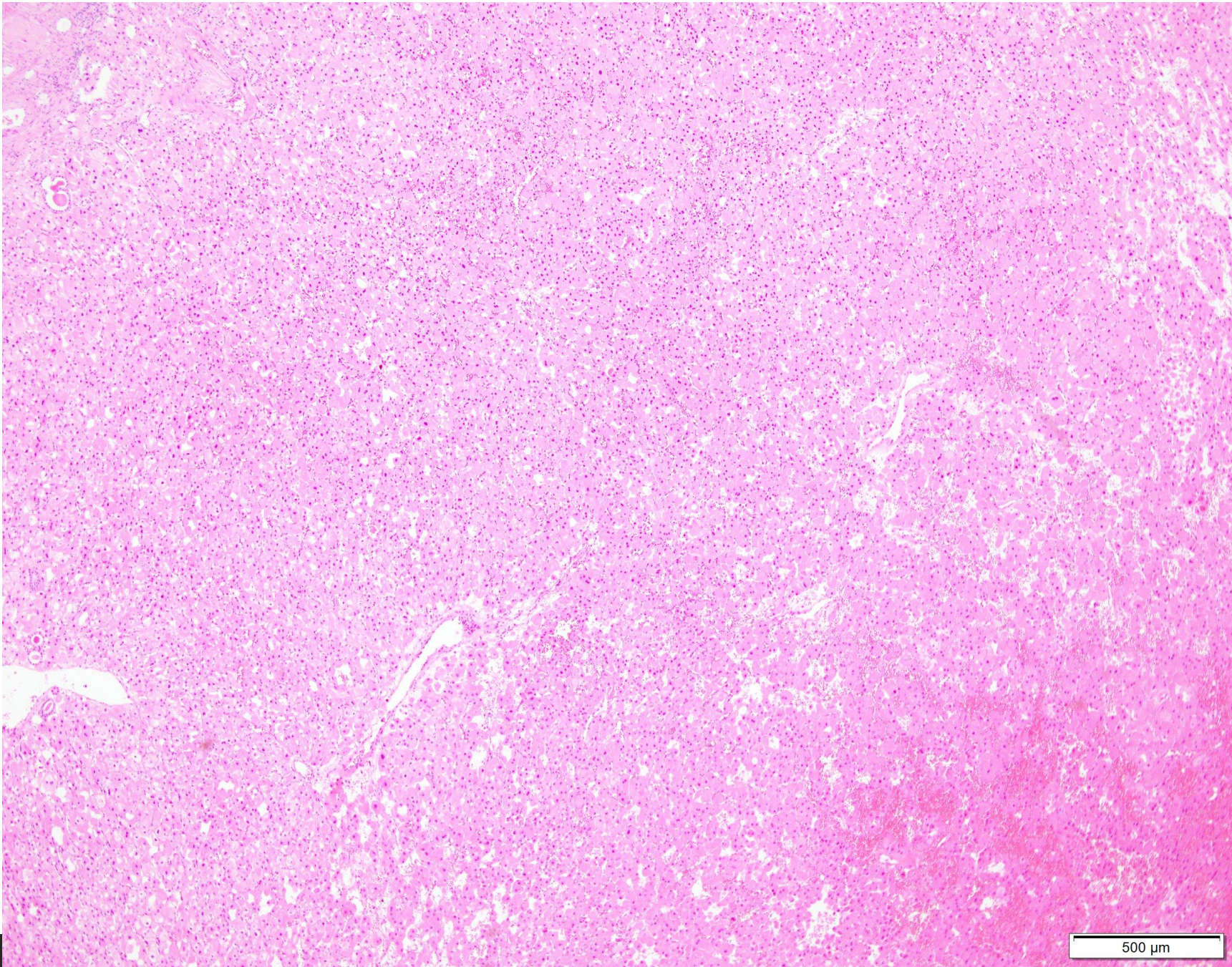


# Case 4

---

67 year old male with history of end stage renal disease and renal transplant found to have a 1.9 cm mass in the left native kidney.

Sheet-like growth pattern  
separated by incomplete  
vascular septa



500  $\mu$ m

Cytologic features are typical

Abundant cytoplasm with prominent cell borders

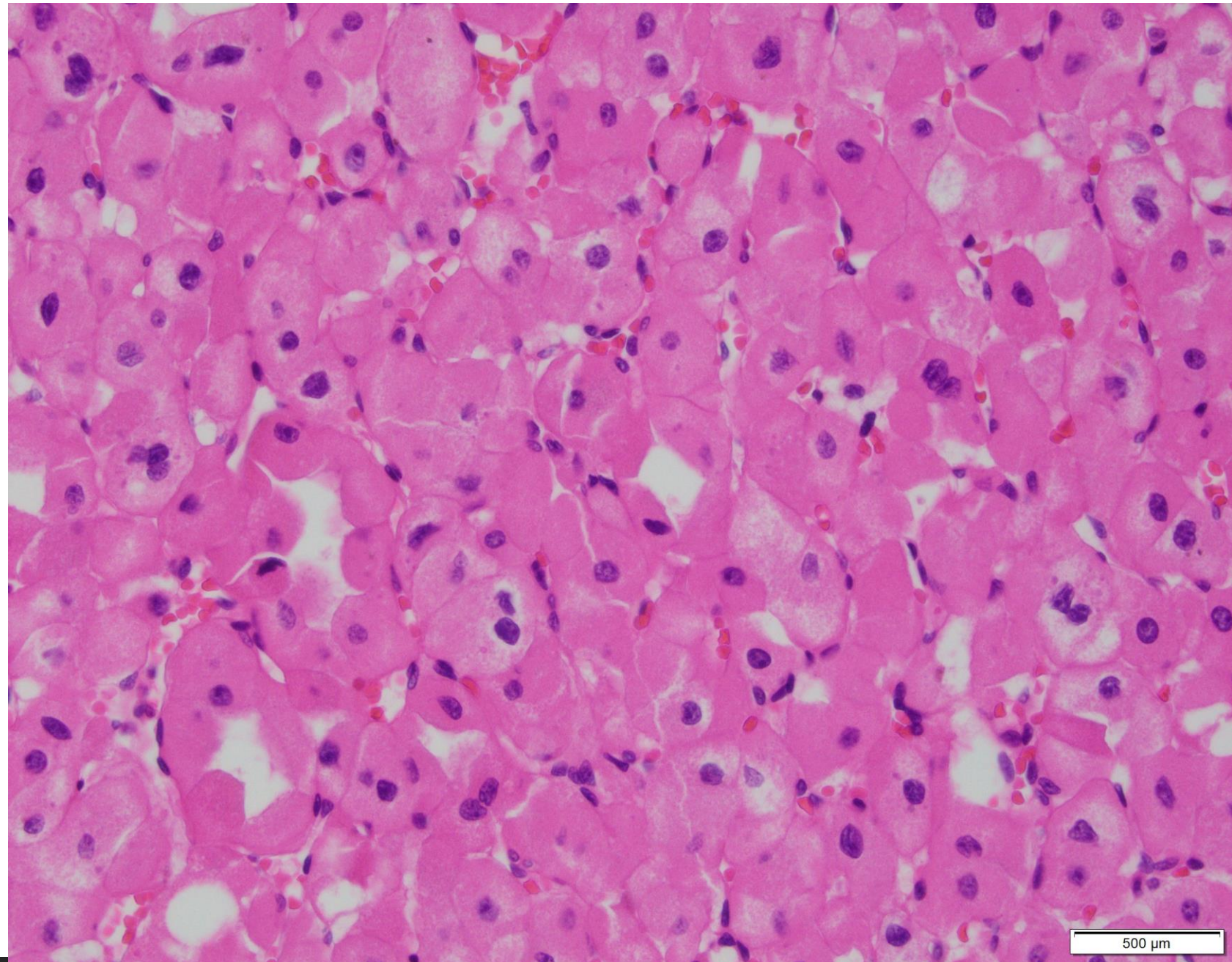
Perinuclear halo

Raisinoid nuclei (irregular wrinkled nuclear membrane with preserved chromatin)

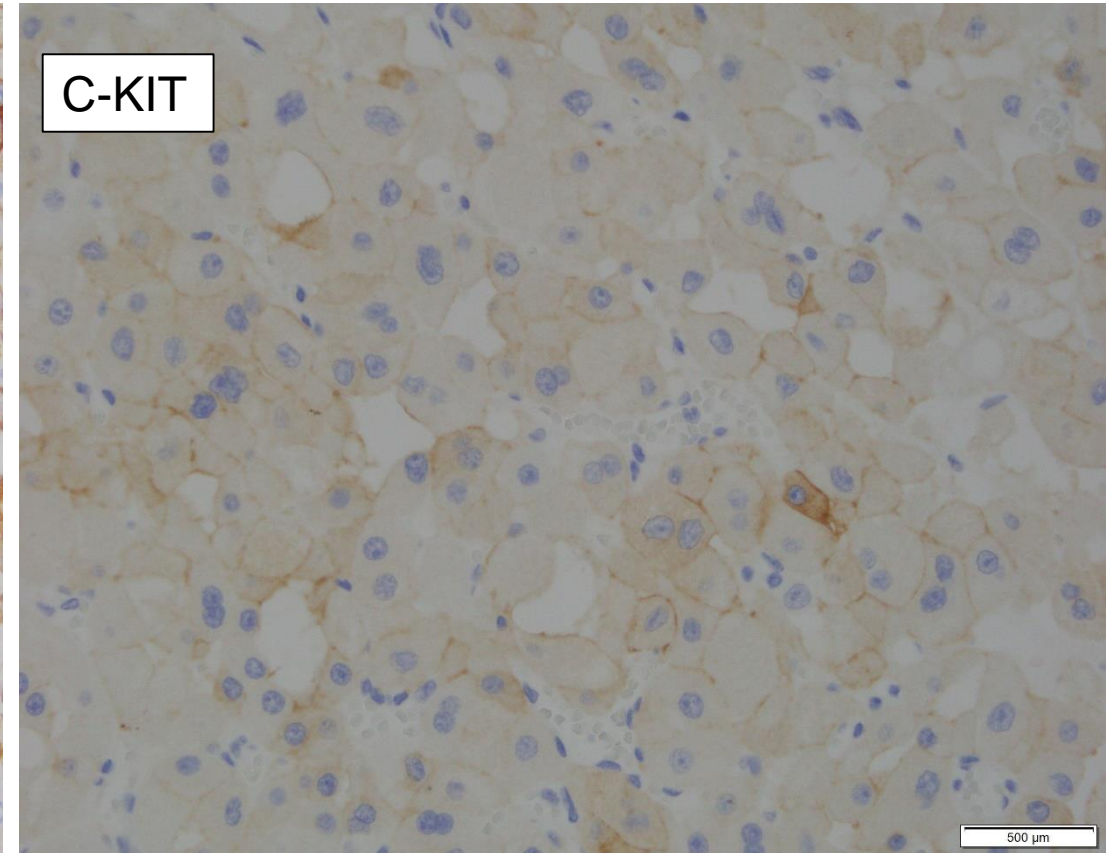
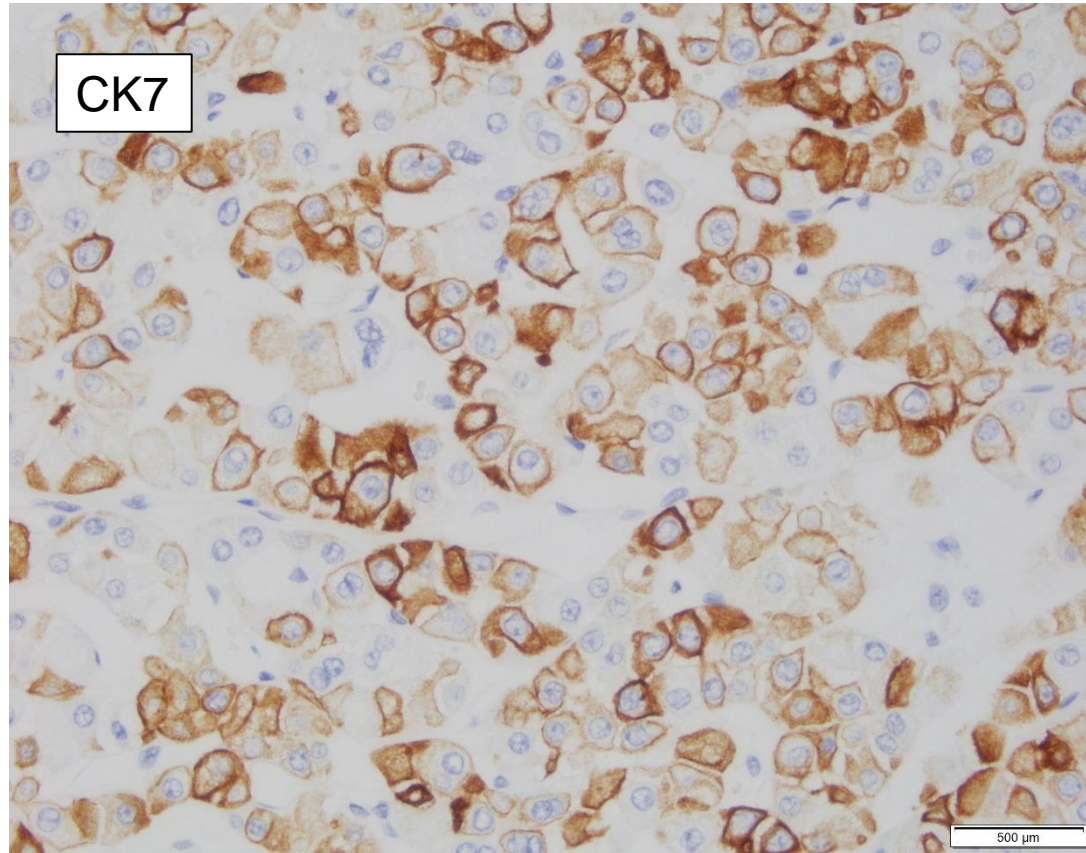
No WHO/ISUP grade (does not accurately reflect their prognosis)

No prognostic difference from classic type chromophobe RCC

May mimic oncocytoma grossly / microscopically

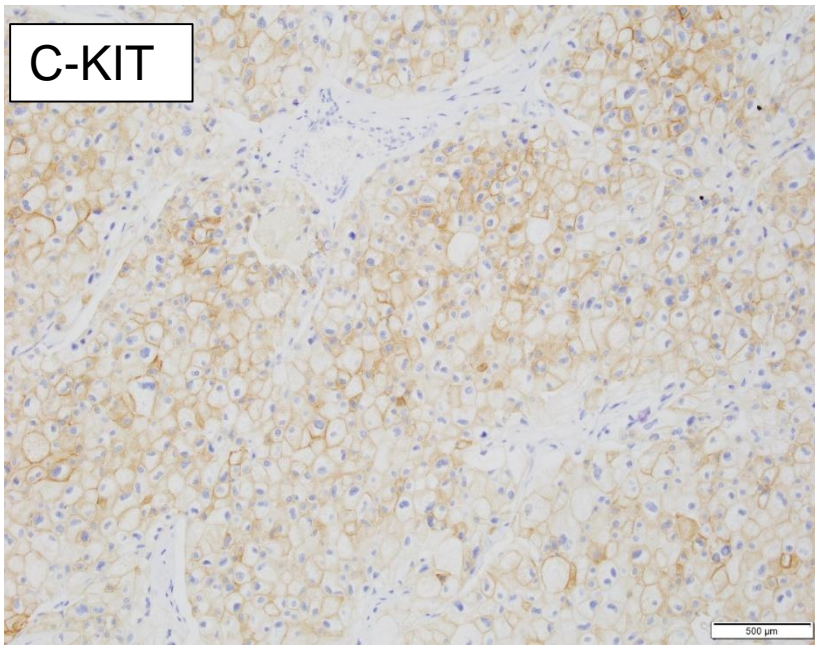


# Chromophobe RCC, Eosinophilic variant

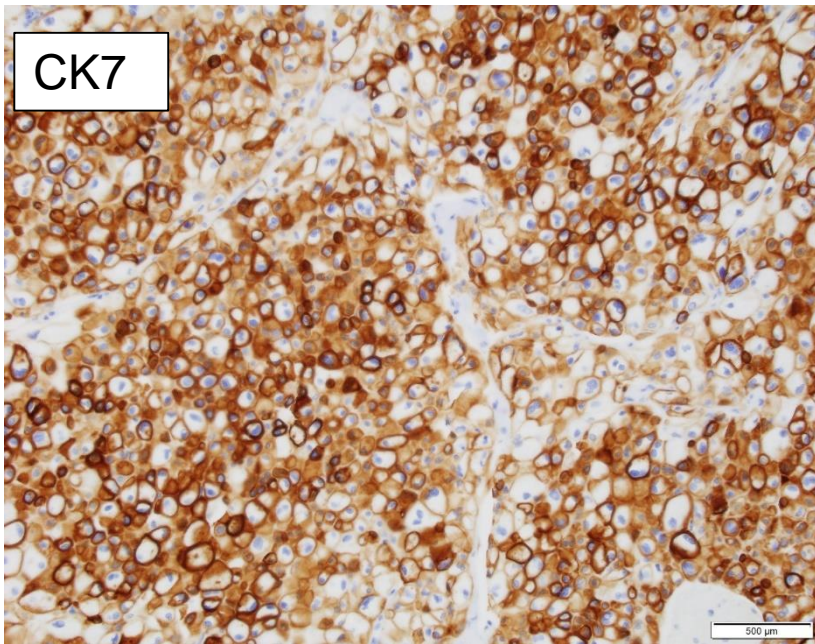


Eosinophilic variant (CK7 positive in ~50% of cases)

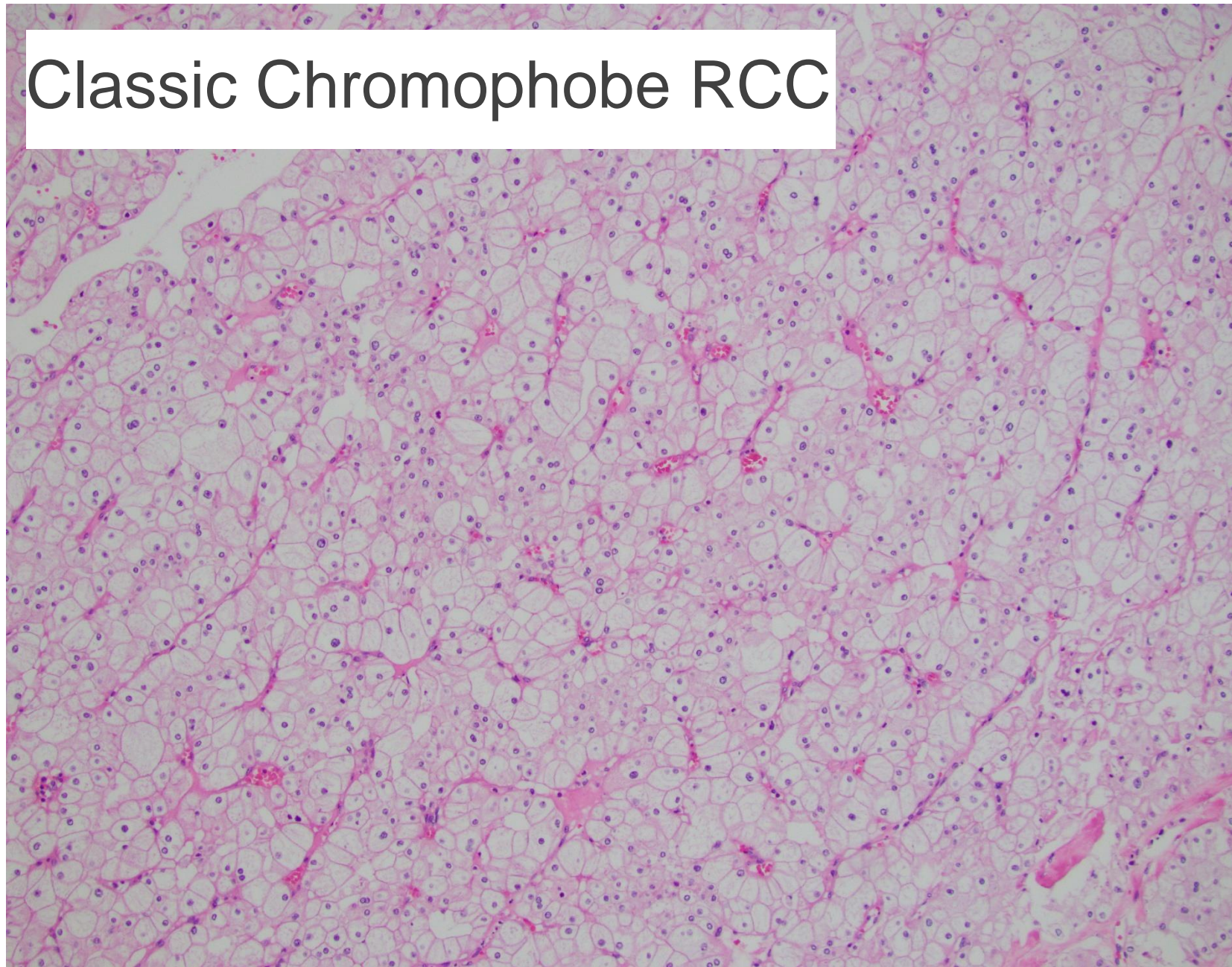
C-KIT



CK7



# Classic Chromophobe RCC

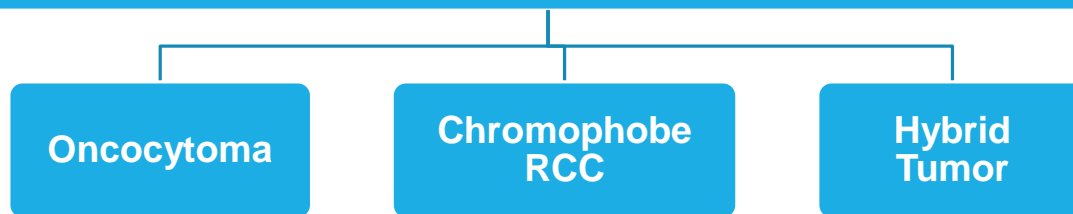


# Eosinophilic/Pink Tumors of the Kidney

- Include a spectrum of non-papillary and papillary tumors ranging from benign oncocytoma to highly aggressive malignancies.
- Recognition of the correct tumor is paramount for patient management.
- Histomorphology
- Immunohistochemistry
- Molecular/FISH Studies



## Low-Grade Non-Papillary Eosinophilic Neoplasms



# Oncocytoma

6th to 7th decade of life

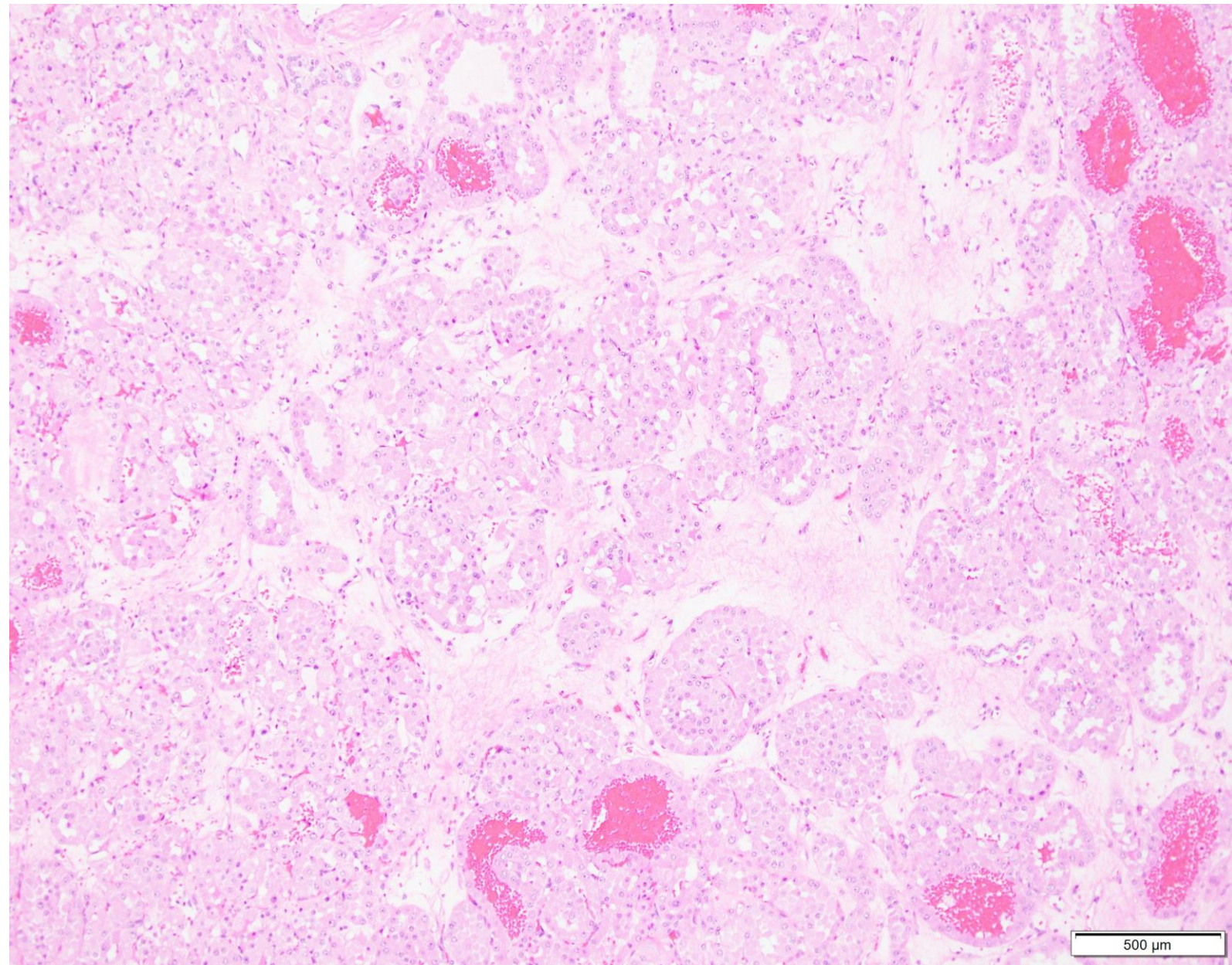
M to F: 2-3X

Mahogany brown, well-demarcated lesion with central stellate scar

Small solid nests within a myxoid and hyalinized stroma

Extrarenal extension with fat involvement (11-20% of cases)

Vascular invasion (minor subset)



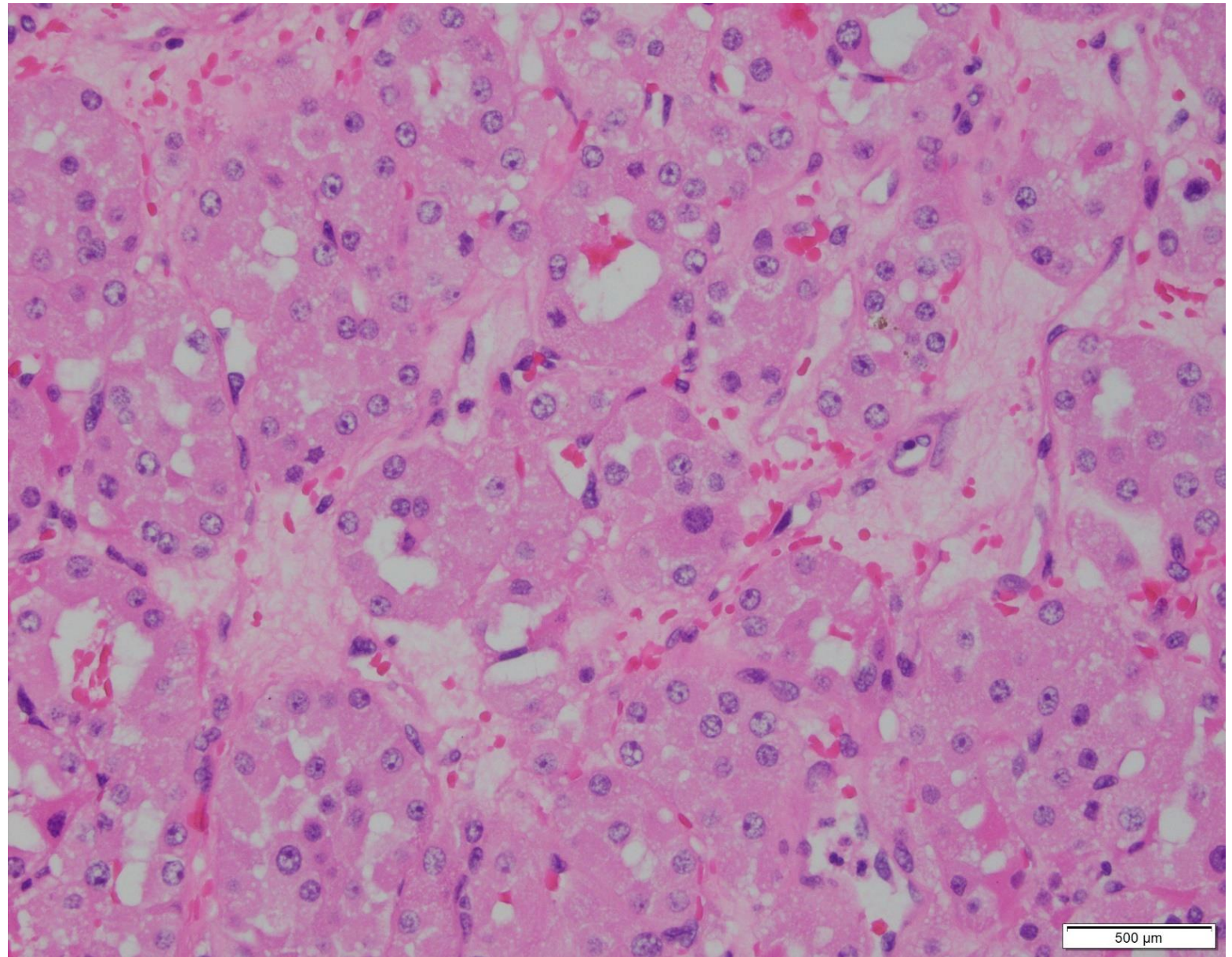
Should not have features that are considered incompatible with this diagnosis

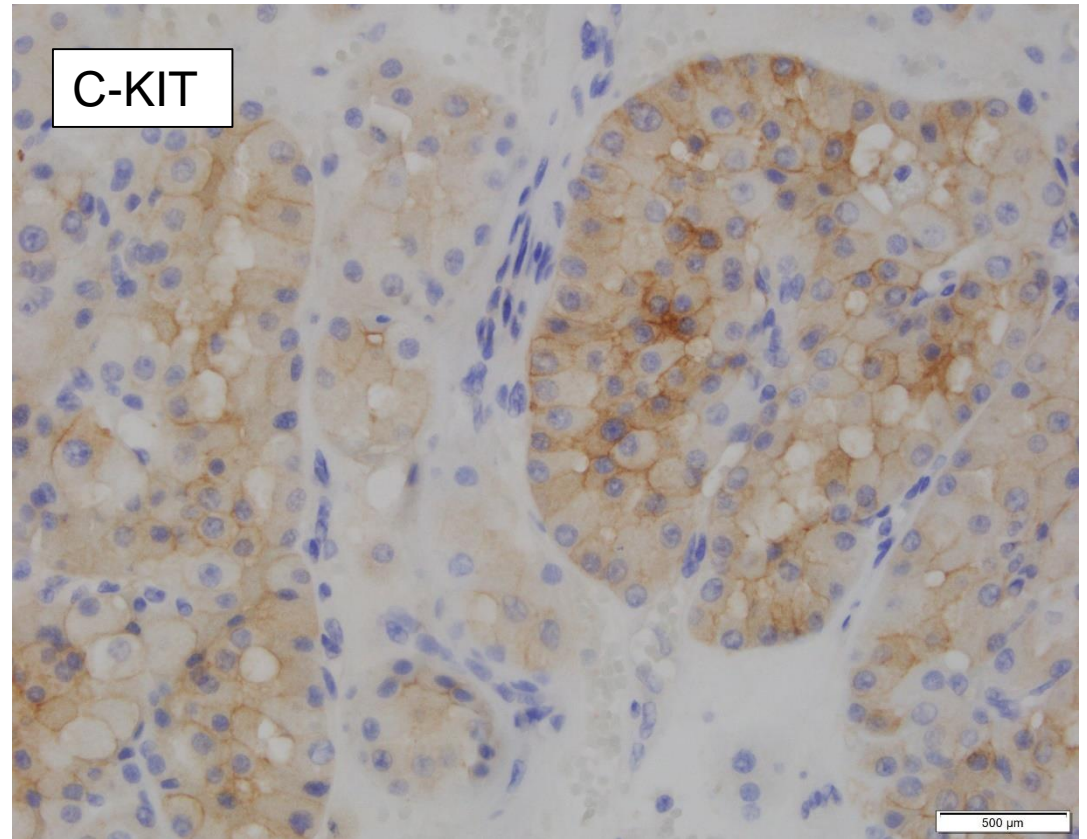
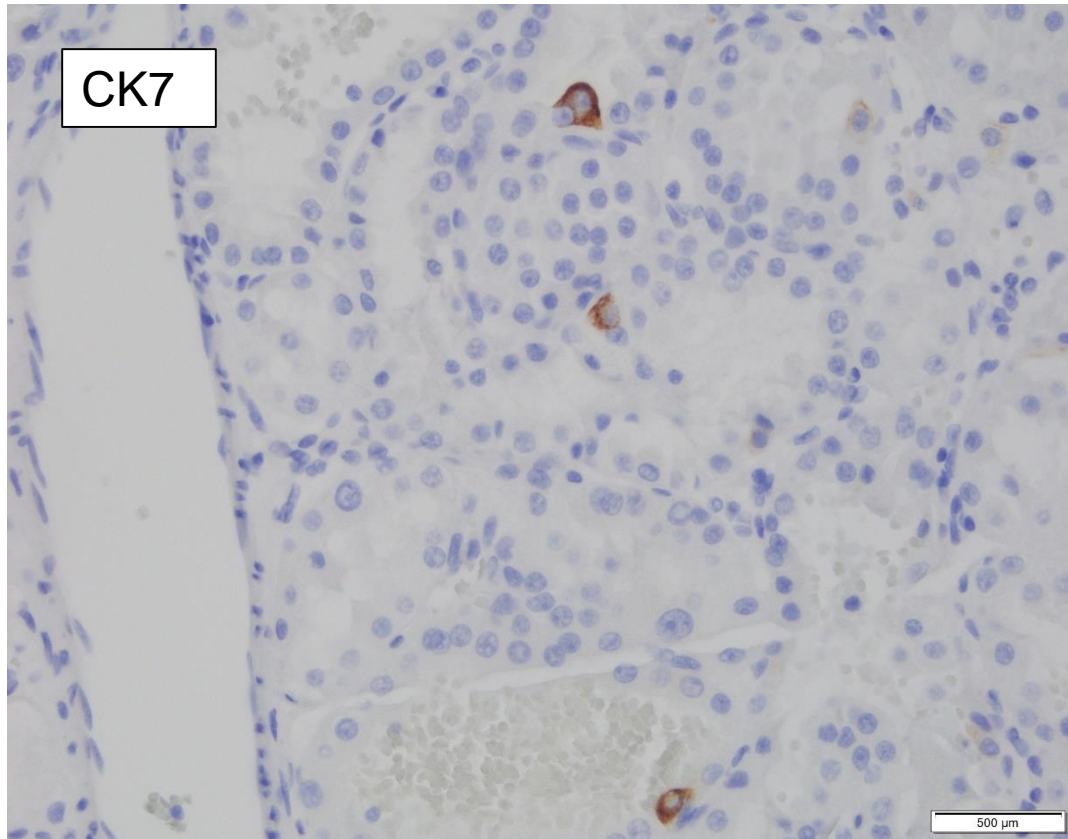
Lack significant areas of clear cells, papillary formation, and necrosis

Voluminous densely eosinophilic cytoplasm

Nuclei are round and uniform; may have prominent nucleoli

Degenerative-appearing nuclear atypia (multinucleated cells with smudgy hyperchromatic nuclei and poorly preserved chromatin detail)





# Hybrid Tumor

Combined morphologic and IHC features of both oncocytoma and chromophobe RCC

May be sporadic

May be seen in patients with Birt-Hogg-Dube (BHD) syndrome

Multifocal oncocytomas and chromophobe RCC

Clinical behavior less aggressive than sporadic carcinomas

BHD syndrome should be suggested when more than one lesion is present unilaterally or bilaterally

Fibrofolliculoma is a typical skin finding

# Low-Grade Non-Papillary Eosinophilic Neoplasms

Tubulocystic  
Carcinoma

ACD-associated RCC

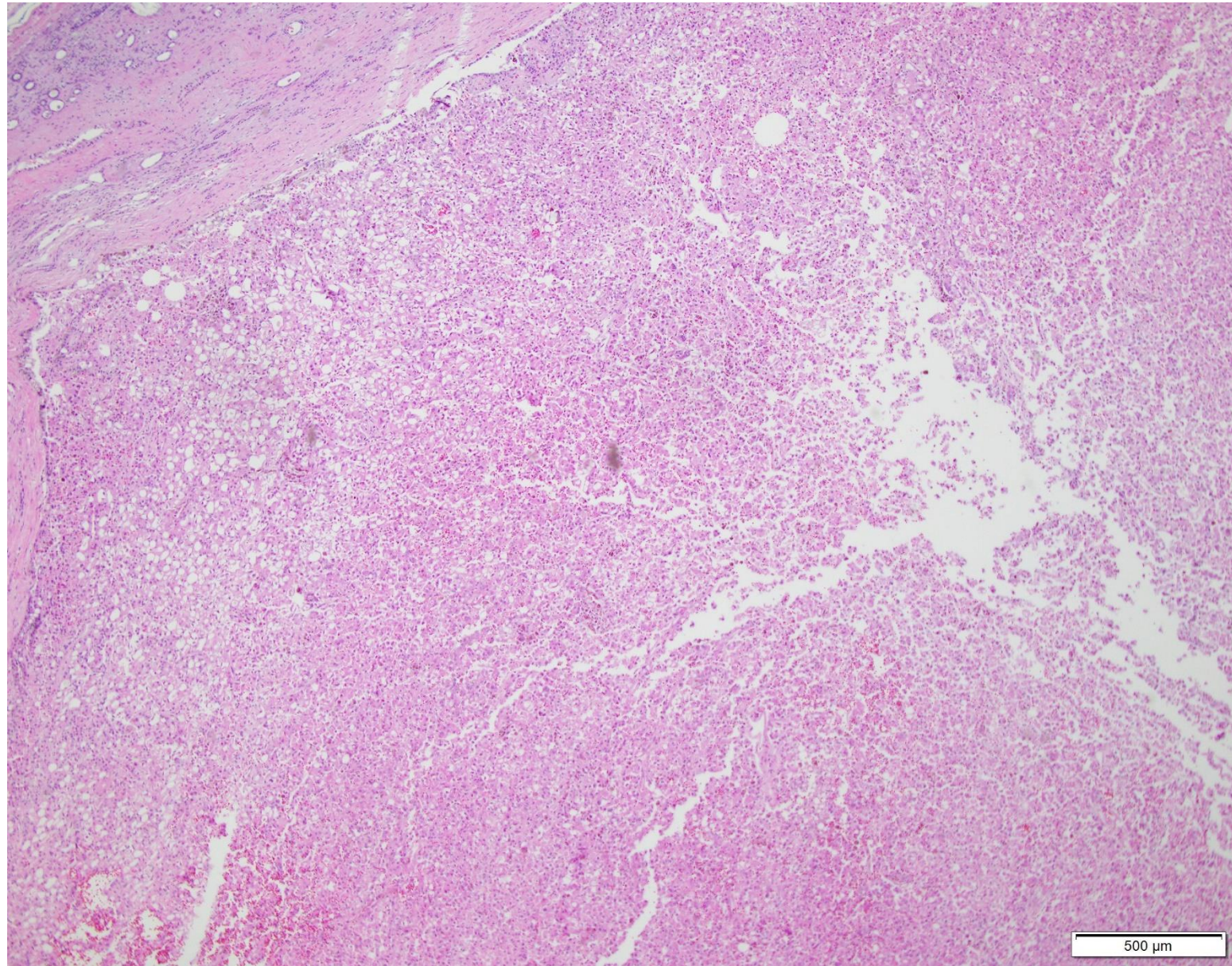
SDH-deficient  
RCC

Epithelioid AML

# ACD-associated RCC

Develops only in the setting of acquired cystic disease

Different architectural patterns within the same tumor (solid and microcystic/macrocytic patterns most common)

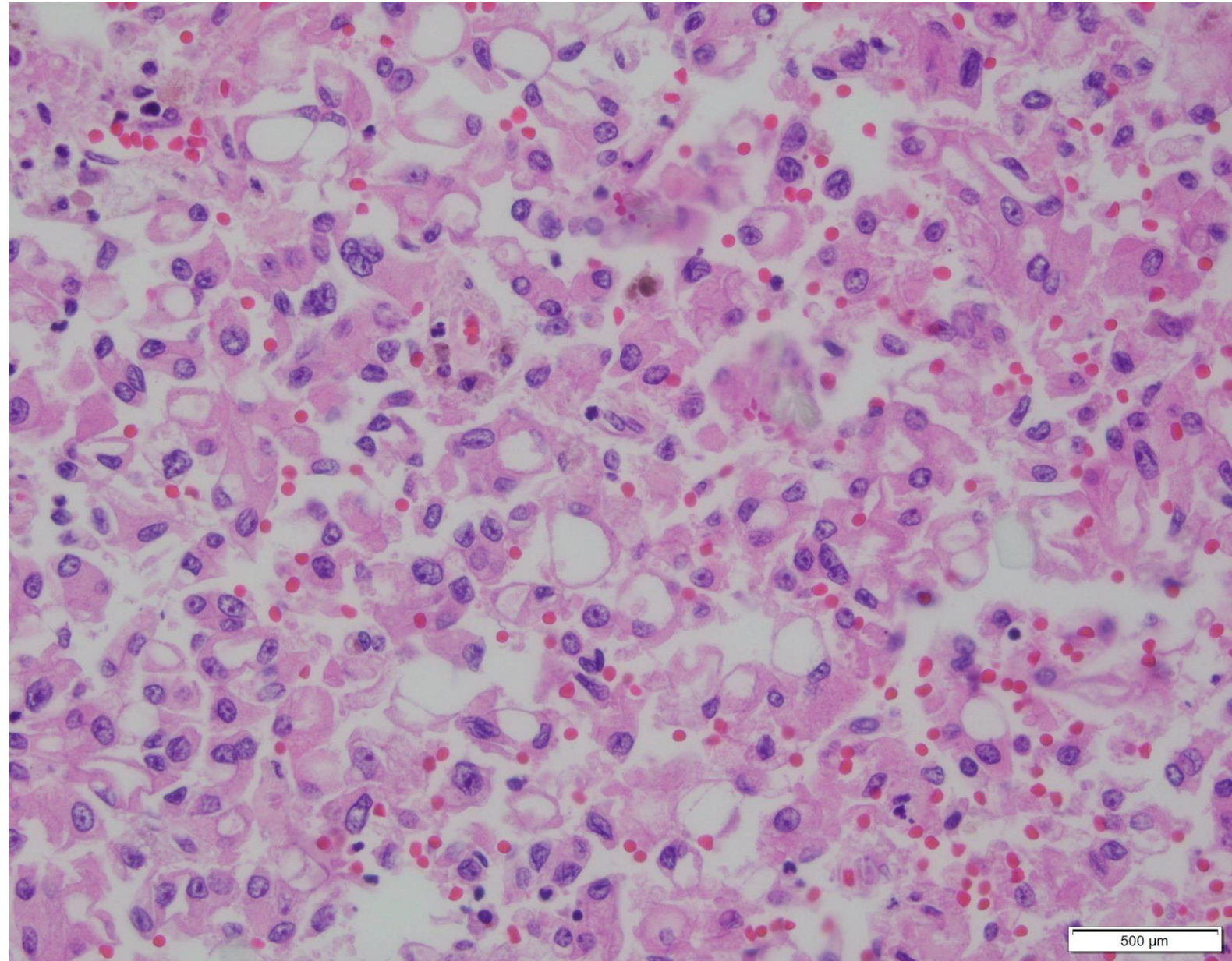


# ACD-associated RCC

Cribriform or sieve-like appearance  
(intra or inter-cytoplasmic  
vacuoles/lumina)

Large cells with abundant deeply  
eosinophilic cytoplasm and large  
nuclei with prominent nucleoli

Intratumoral oxalate crystals





# SDH-deficient RCC

4th decade of life

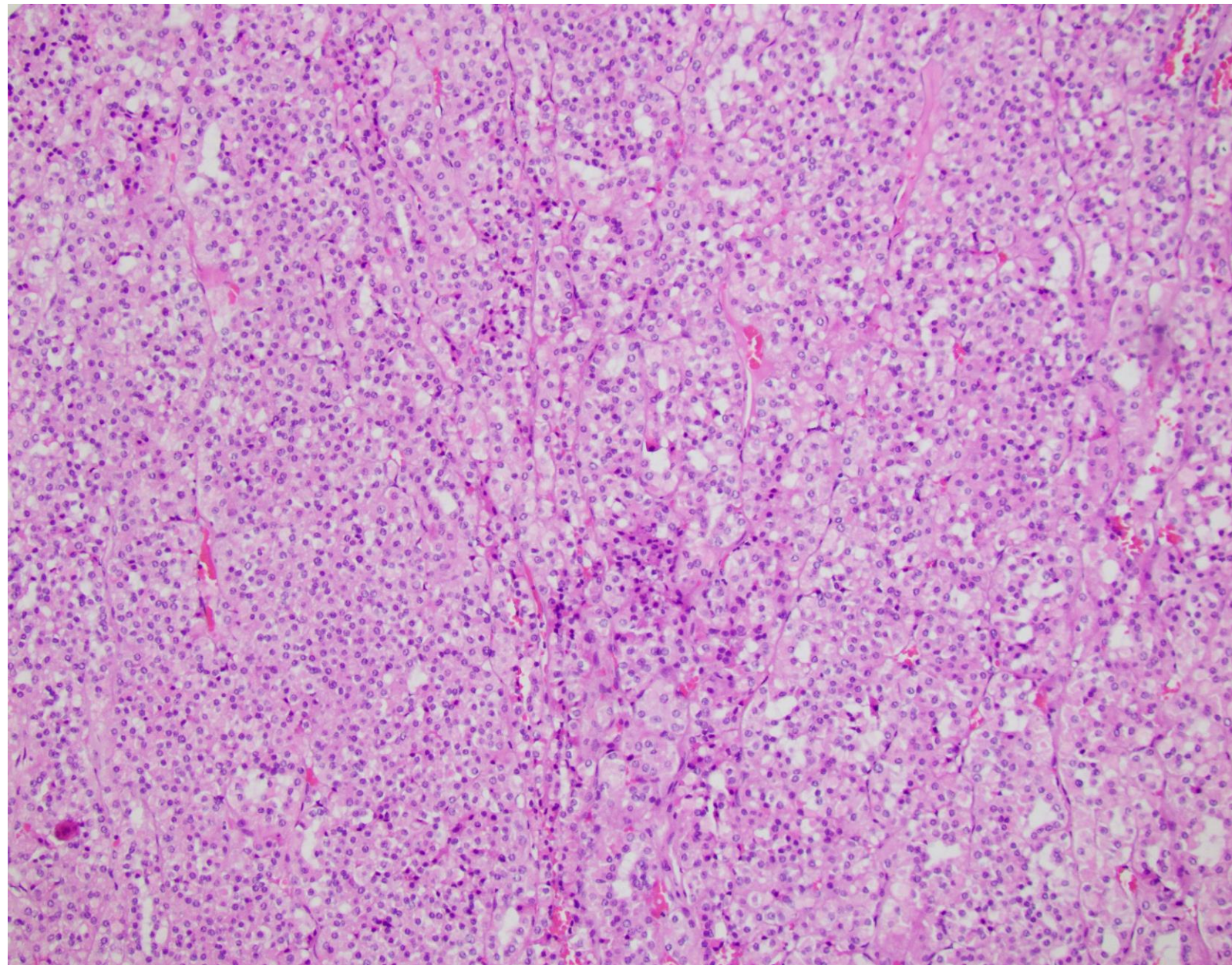
M to F: 1.8:1

Well circumscribed with a lobulated or pushing margin

SDHB IHC is negative

Long term follow-up for other SDH deficient neoplasms (paraganglioma, SDH-deficient GIST, and pituitary adenoma)

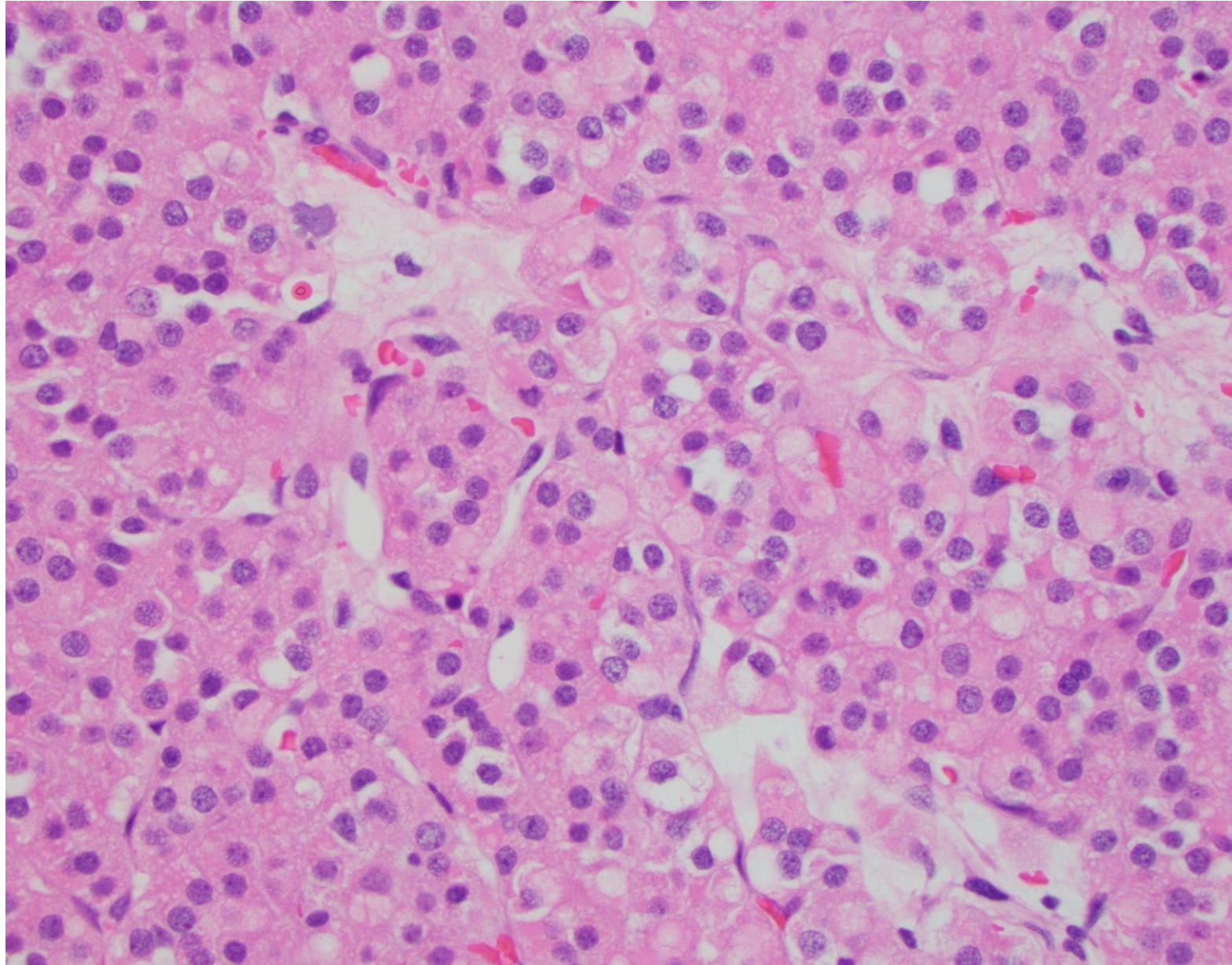
Favorable prognosis (75% cases)



# SDH-deficient RCC

Smooth nuclear contours, evenly dispersed chromatin, and inconspicuous nucleoli (neuroendocrine-like)

Cytoplasmic vacuoles or flocculent inclusions containing eosinophilic fluid (bubbly appearance) is a distinctive feature



# Epithelioid AML

4th decade of life (Triphasic AML are seen in the 6th decade of life)

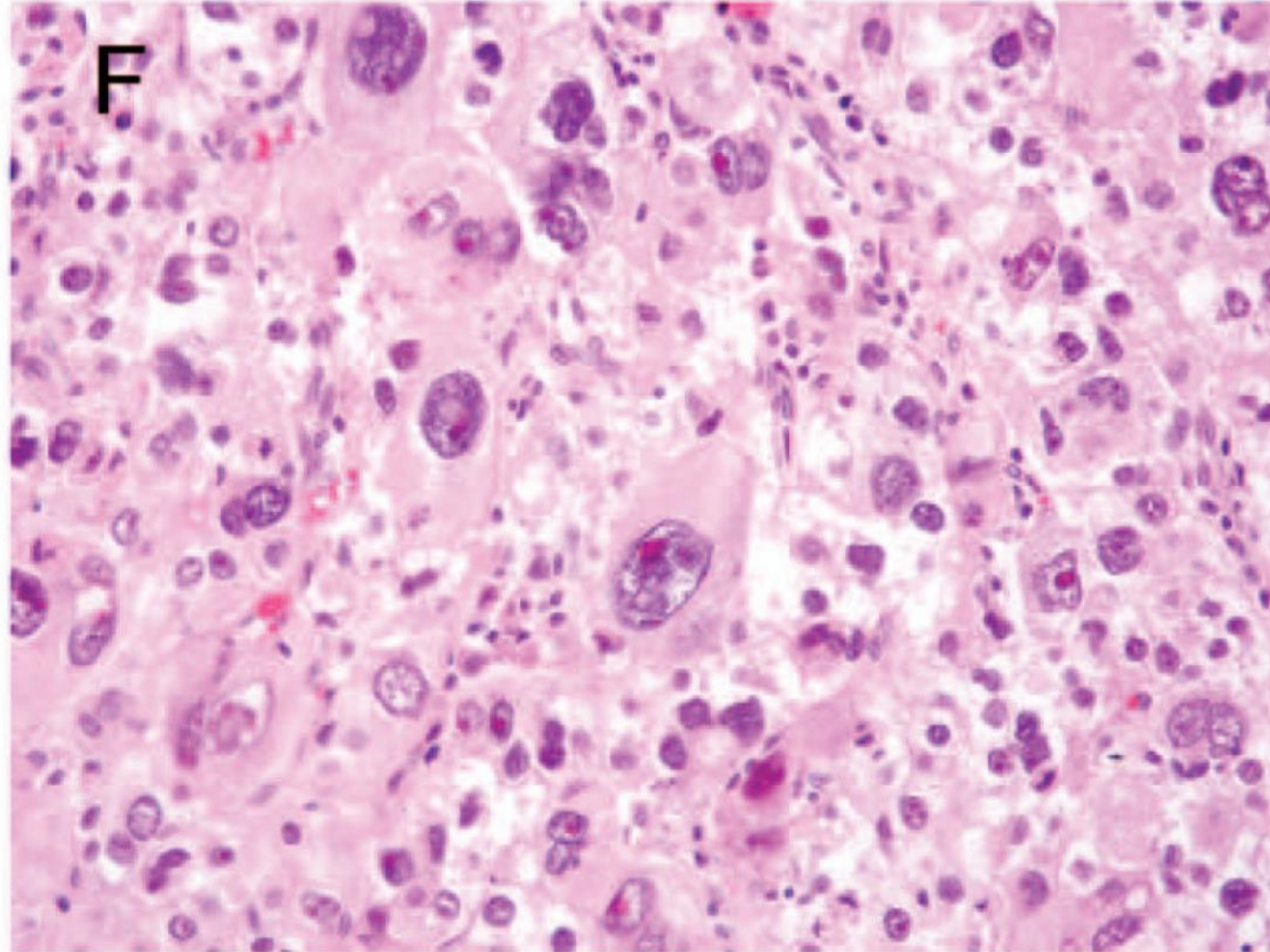
More commonly seen in tuberous sclerosis patients

Lacks significant amount of intratumoral fat and malformed vessels

2 types of cells in Epithelioid AML: (1) clear cells with finely granular cytoplasm and small monomorphic nuclei and (2) eosinophilic cells with abundant cytoplasm, epithelioid morphology, and large nuclei with prominent nucleoli (amoeboid cells)

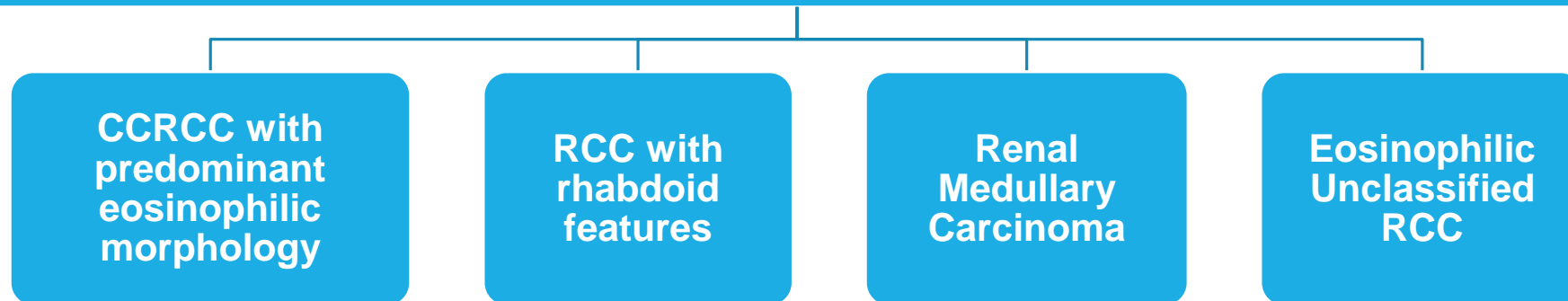
Pancytokeratin, EMA, and PAX8 negative

HMB45 and Melan-A positive



Kryvenko et al.

# High-Grade Non-Papillary Eosinophilic Neoplasms



# CCRCC with predominant eosinophilic morphology

High grade tumors can acquire eosinophilic morphology

Nested pattern of growth

Rich sinusoidal vasculature surrounding the nests

IHC similar to conventional clear cell RCC

# RCC with rhabdoid features

Dedifferentiation of any type of RCC

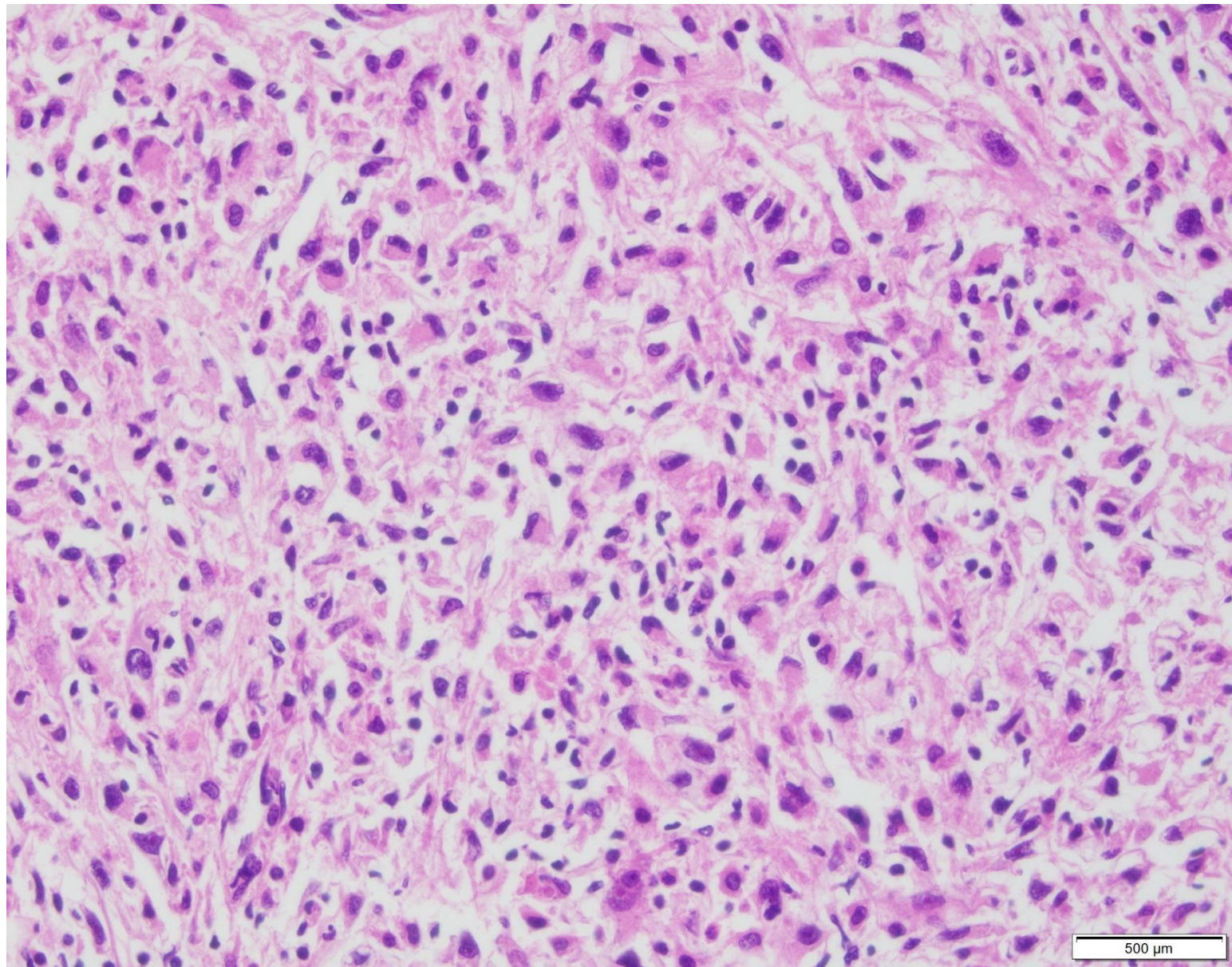
No specific IHC

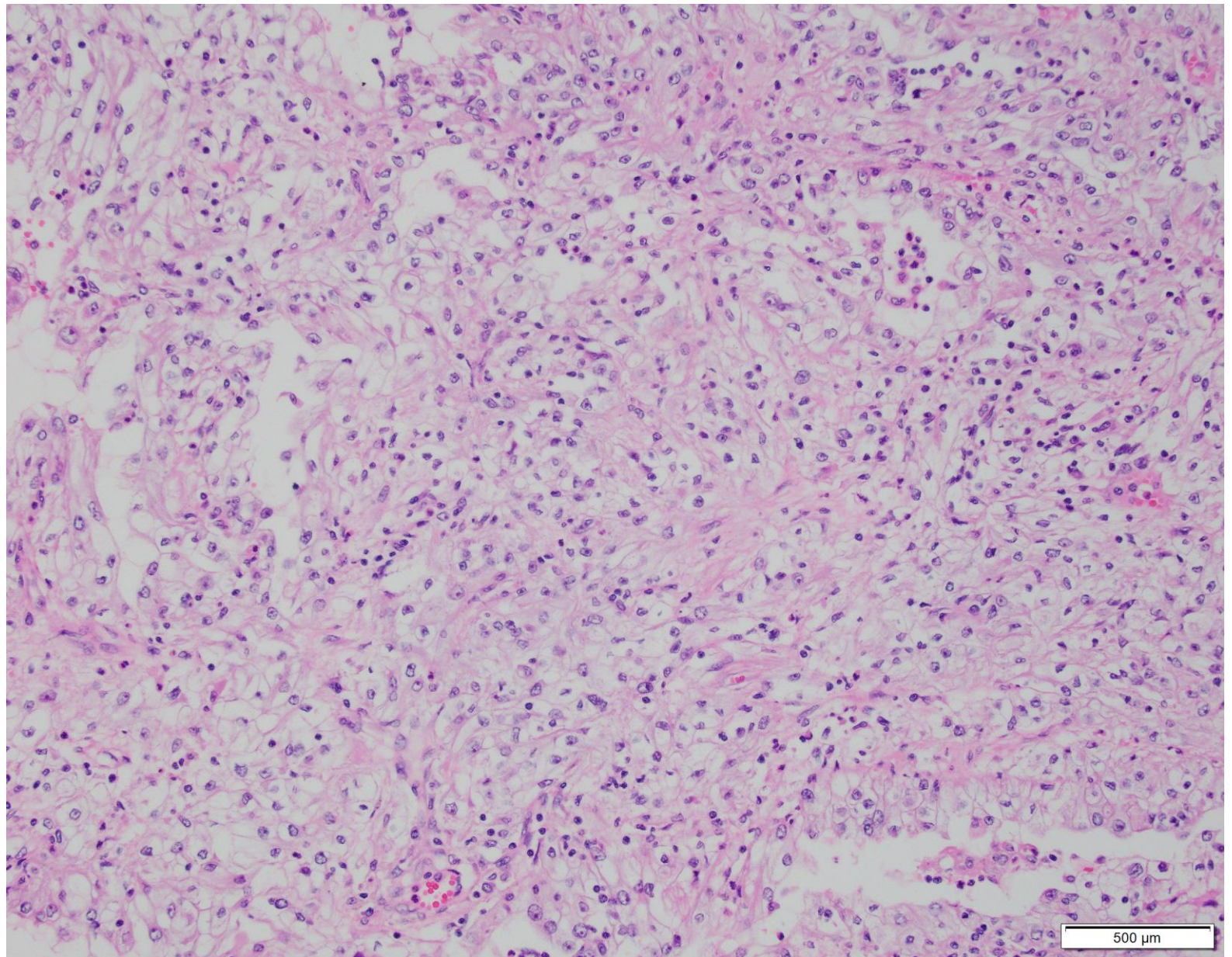
Extensive sampling to find the well differentiated RCC component

Rhabdoid cell: abundant eosinophilic cytoplasm and peripherally located nucleus (resembles rhabdomyoblast)

WHO/ISUP grade 4

INI-1 is retained





# Renal Medullary Carcinoma

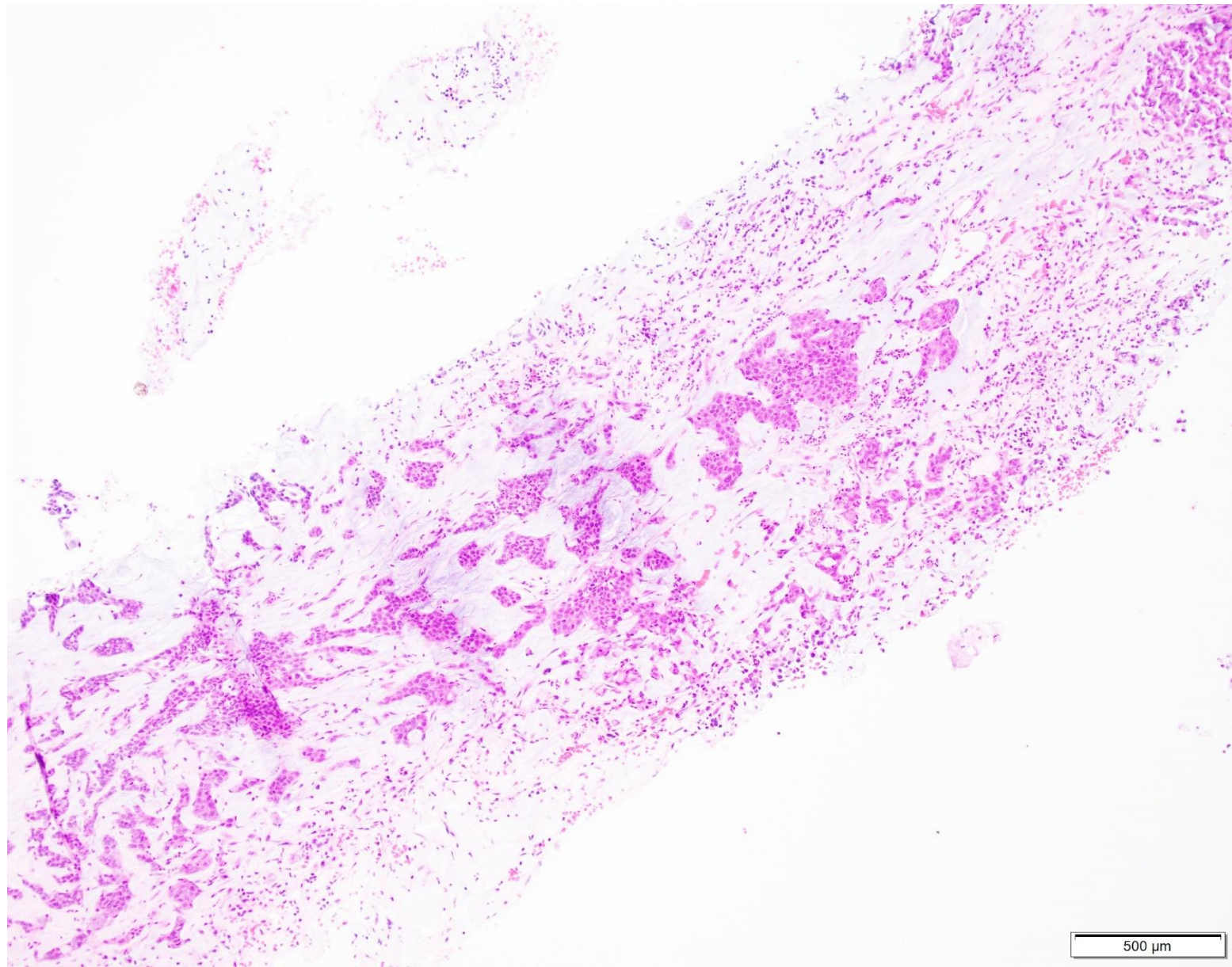
M to F: 2:1

Highly aggressive carcinoma

Centered in the renal medulla

Associated with Sickle cell trait and related hemoglobinopathies

In a patient with no evidence of sickle cell trait or disease (as ruled out by family history and serum electrophoresis) it is diagnosed as unclassified renal cell carcinoma with renal medullary phenotype





# Renal Medullary Carcinoma

Infiltrating tubules, glands, and tubulopapillary structures

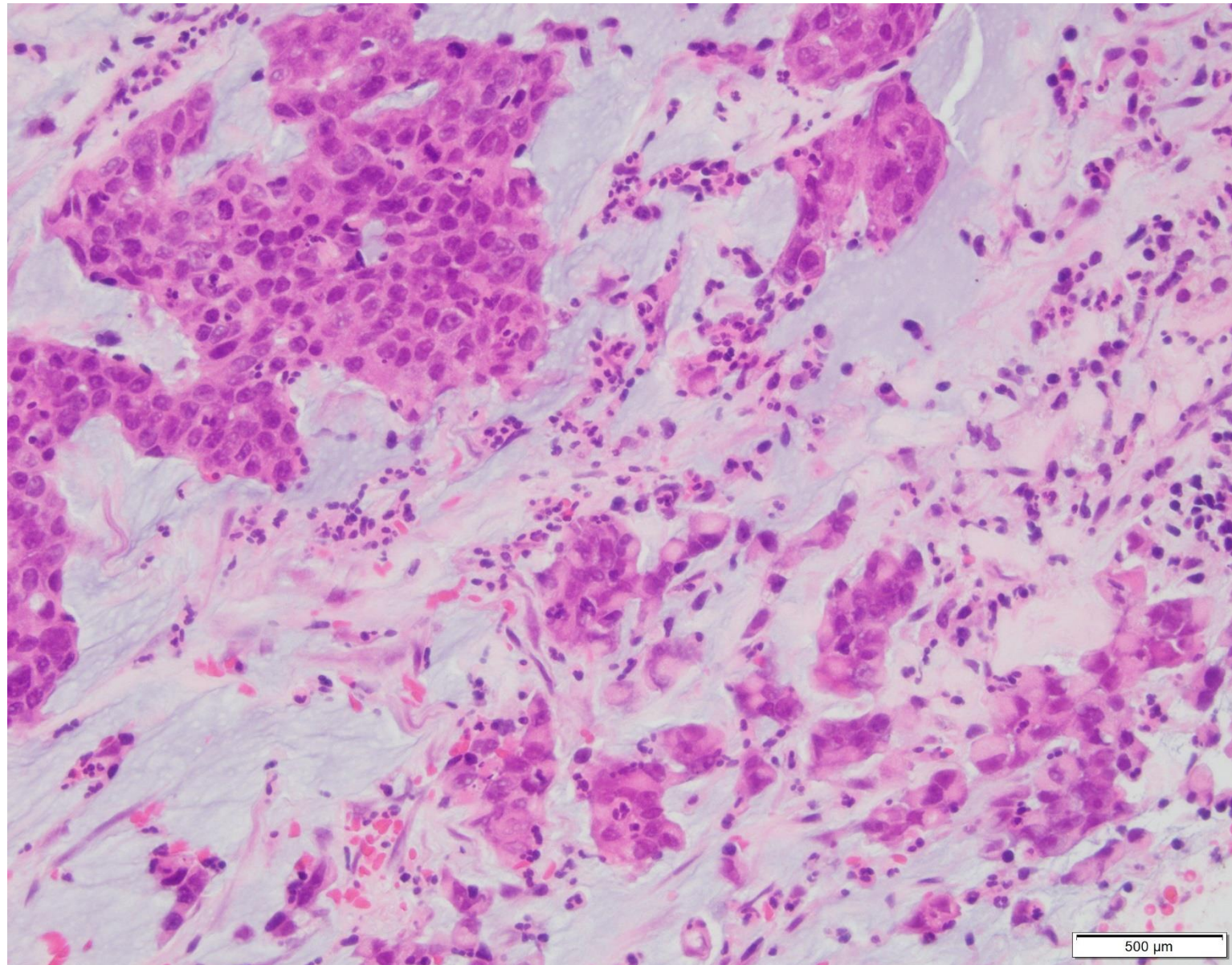
Associated necrosis, desmoplasia, and inflammation

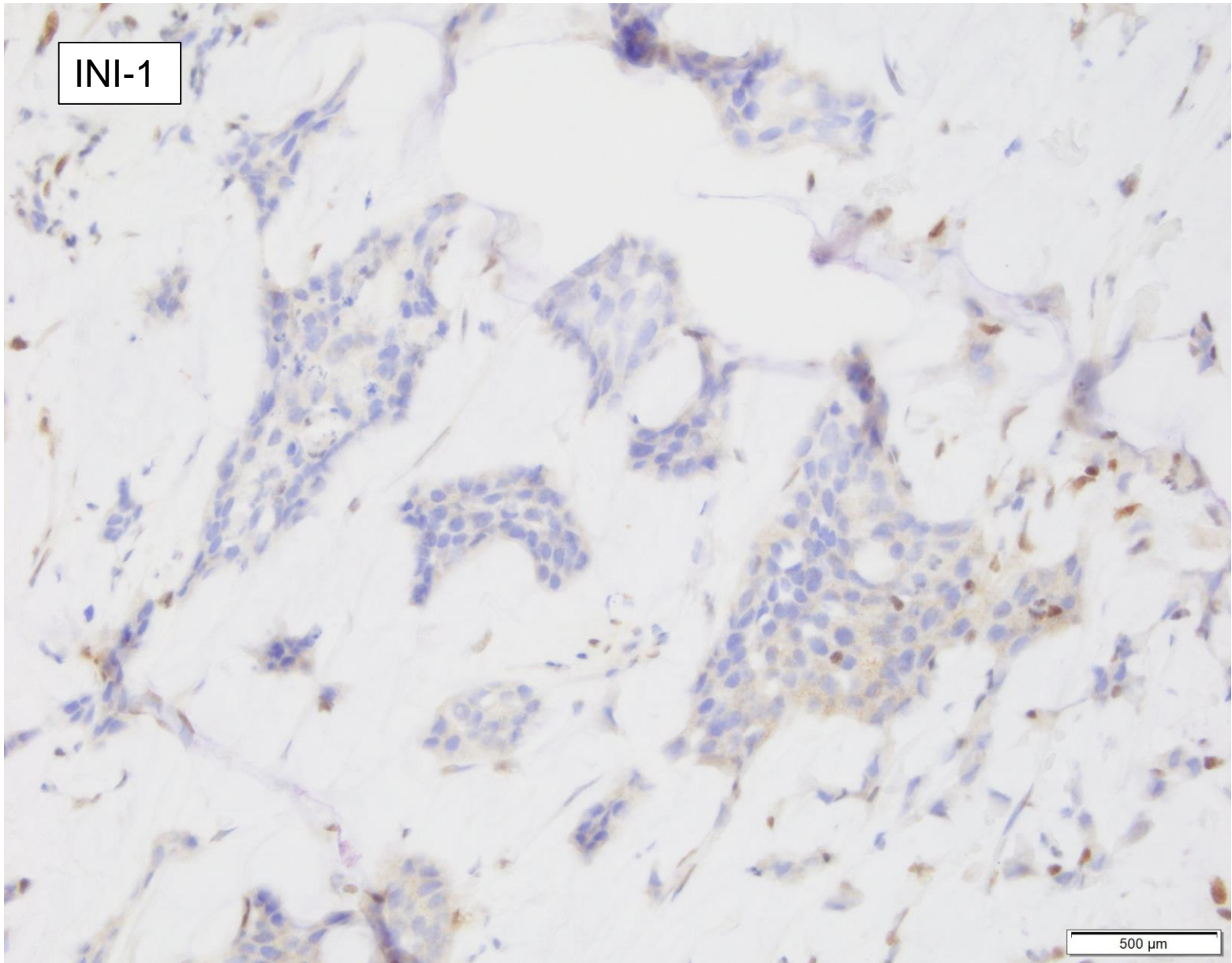
Pronounced cytologic atypia with eosinophilic cytoplasm and prominent nucleoli

Myxoid stromal response associated with a neutrophil-predominant inflammatory infiltrate

Loss of SMARCB1 (INI-1)

OCT3/4 Positive





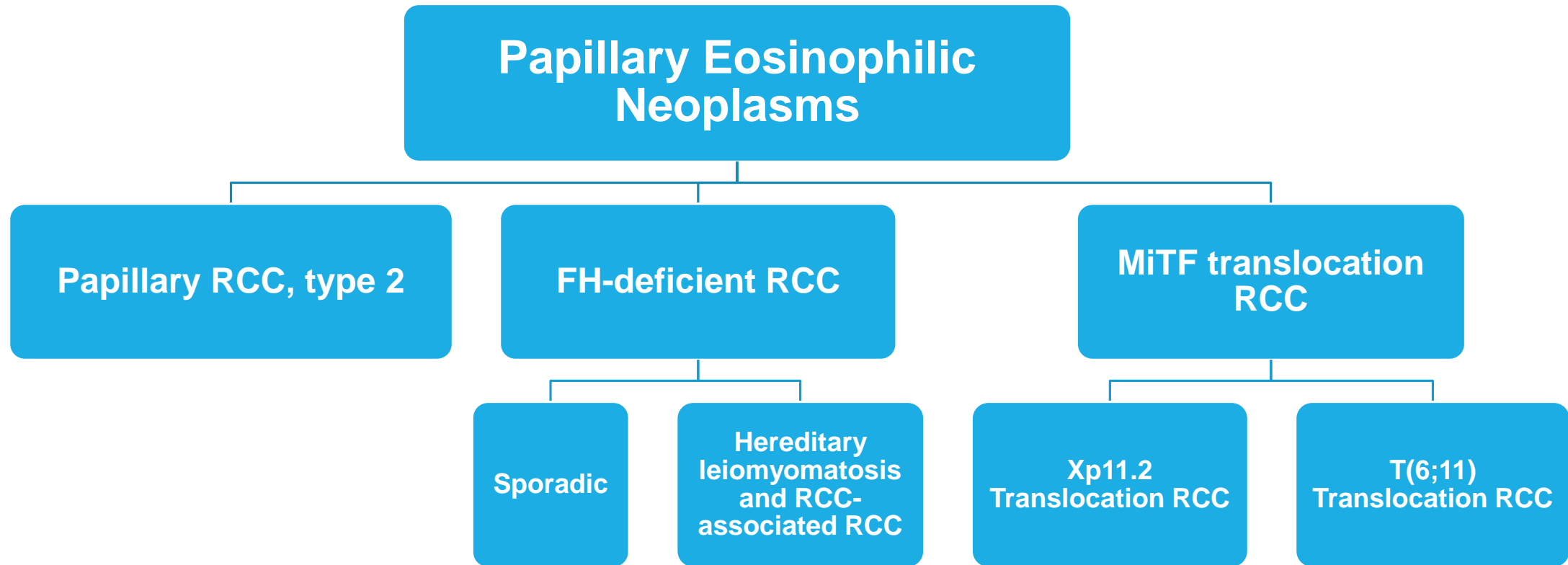
# Eosinophilic Unclassified RCC

Morphologic features that do not fit into any recognized RCC class

Combination of two or more morphologic types by light microscopy

Purely sarcomatoid carcinoma

# Papillary Eosinophilic Neoplasms



# FH-deficient RCC

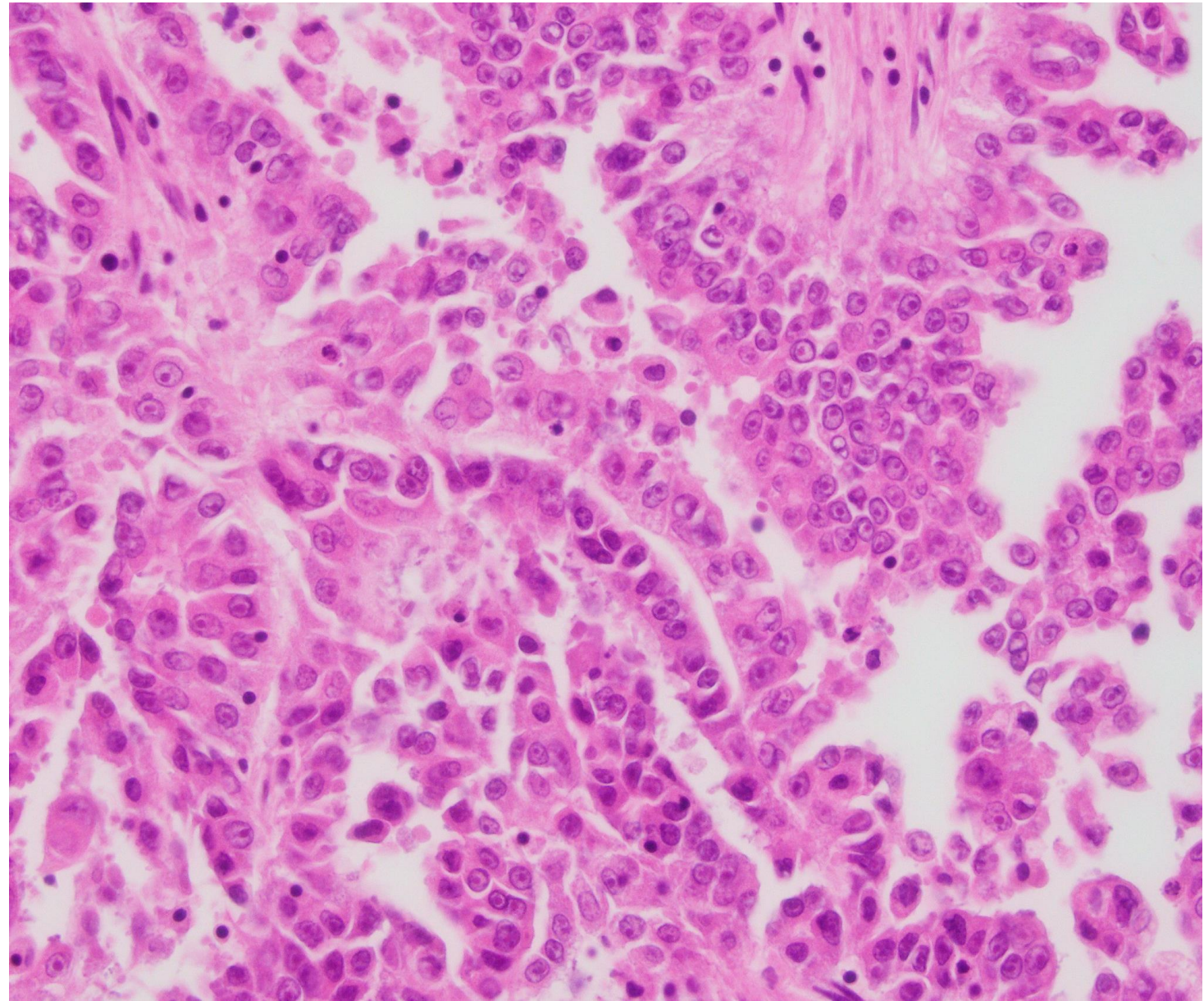
6th to 7th decade of life (sporadic)

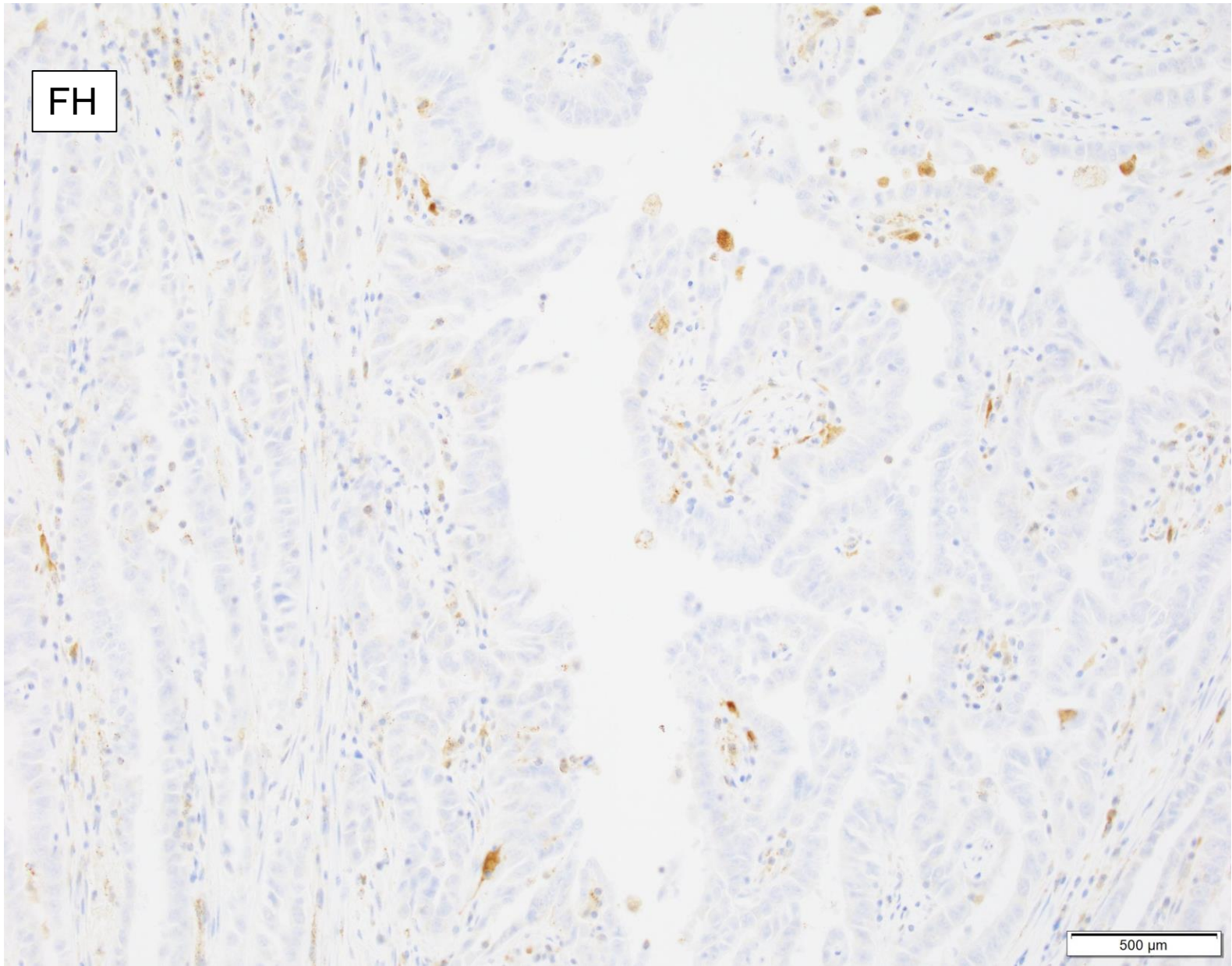
4th decade of life (Germline/Hereditary)

Cutaneous and uterine leiomyomas

Aggressive renal tumors

Prominent Eosinophilic nucleoli with perinucleolar clearing





# T(6;11) Translocation RCC

Less heterogeneous than Xp11.2

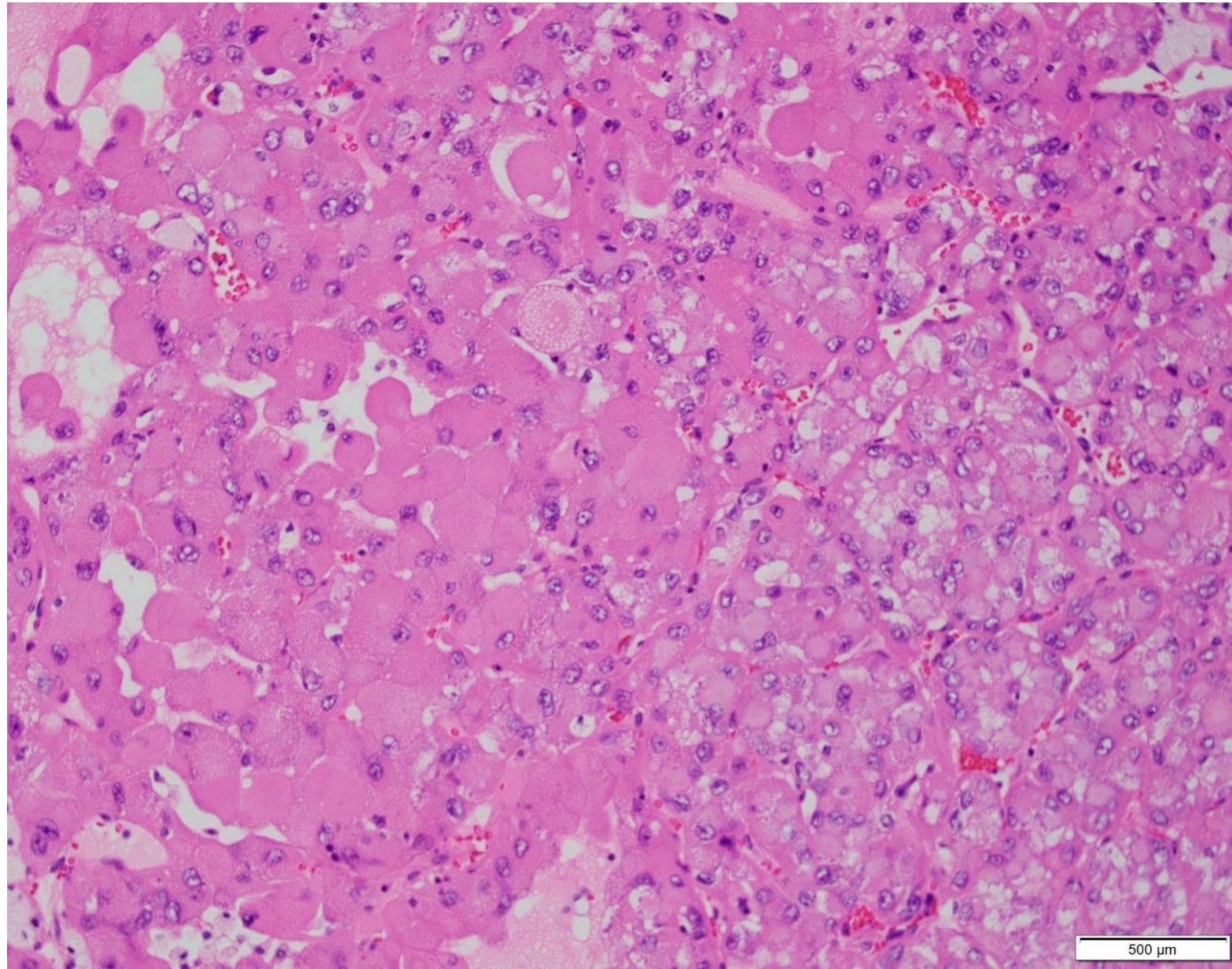
Alpha-TFEB gene fusion

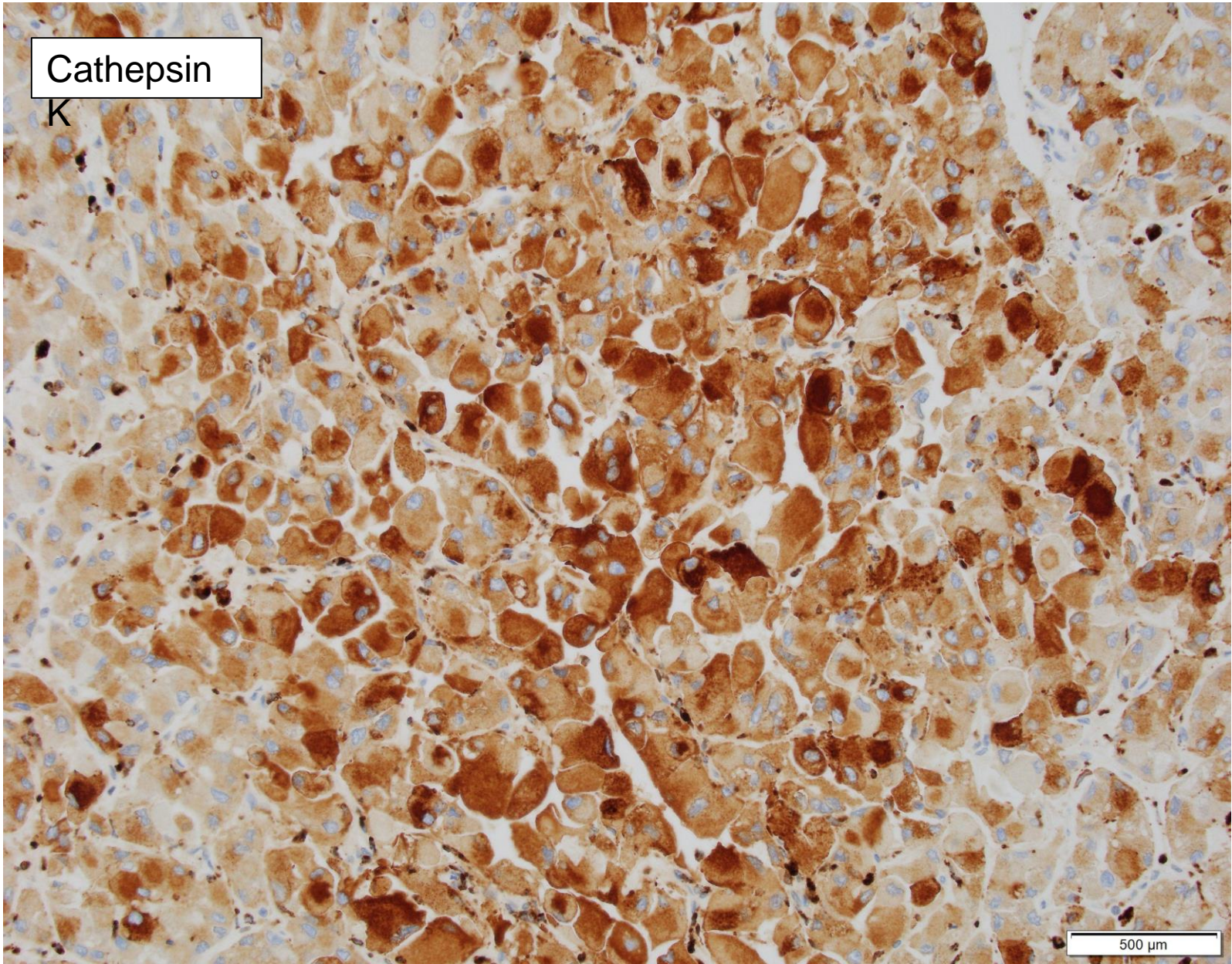
Biphasic pattern (large epithelioid eosinophilic and clear cells + small eosinophilic cells with small hyperchromatic nuclei (often have rosette like arrangement with accumulation of basement membrane like material)

Cathepsin K IHC (100% cases)

Melanocytic markers (HMB45 and Melan-A)

TFEB FISH







# Take home point

- Eosinophilic/oncocytic tumors of the kidney represent a wide spectrum ranging from benign to highly aggressive malignancies.
- Recognition of the correct tumor is paramount for patient management.
- Histomorphology
- Immunohistochemistry
- Molecular/FISH Studies



**EMORY**  
UNIVERSITY  
SCHOOL OF  
MEDICINE

**Department of  
Pathology and  
Laboratory  
Medicine**



Georgia Association of Pathology

EMORY

.....

# 2020 Virtual Pathology Course

**FAISAL SAEED, MD**

**GENITOURINARY  
PATHOLOGIST**

**ASSISTANT PROFESSOR**

# Case 5

---

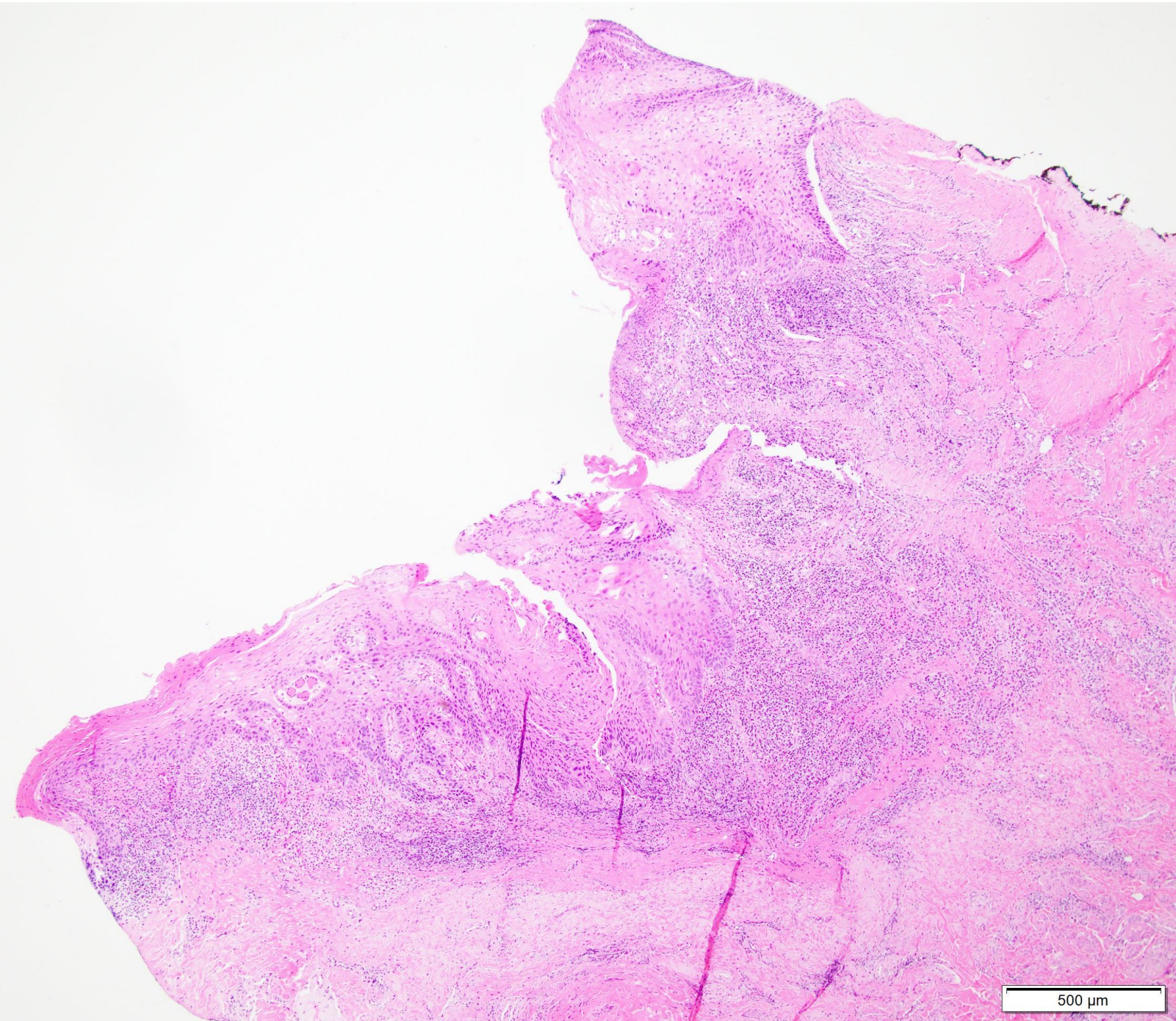
67 year old male with painful non-healing ulcer along the ventral left coronal sulcus of the penis.

Thickened epithelium with  
parakeratosis

Elongated and anastomosing rete  
ridges

Atypical basal layer cells

Atypia seems to be present only in  
lower levels

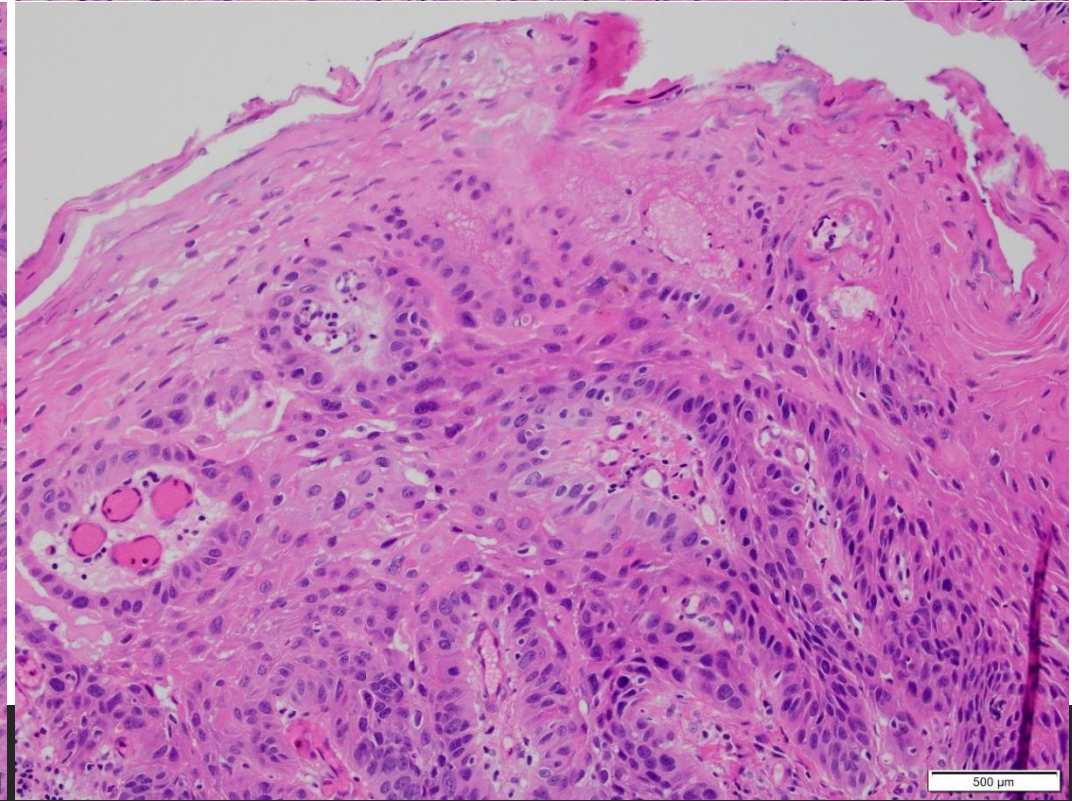
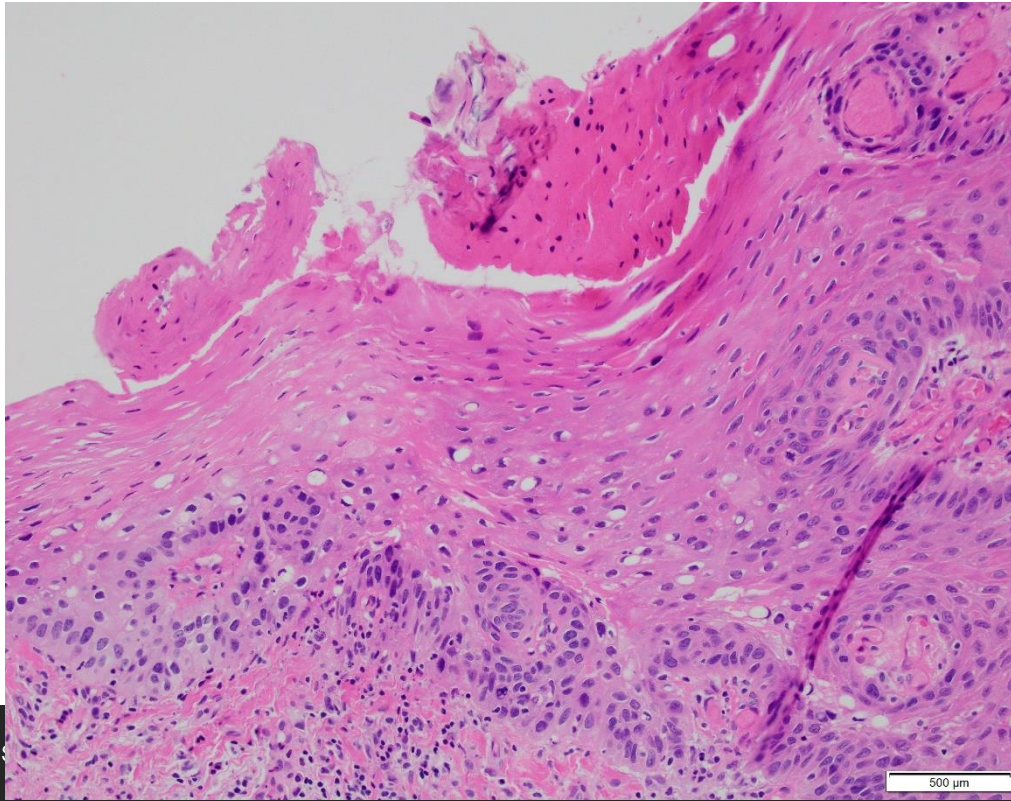
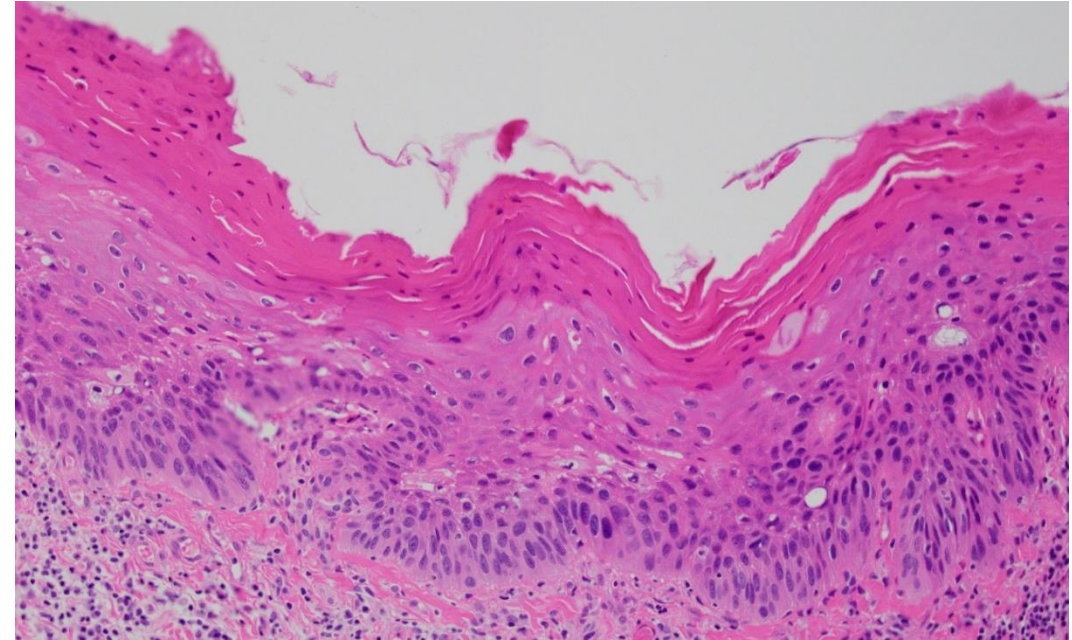


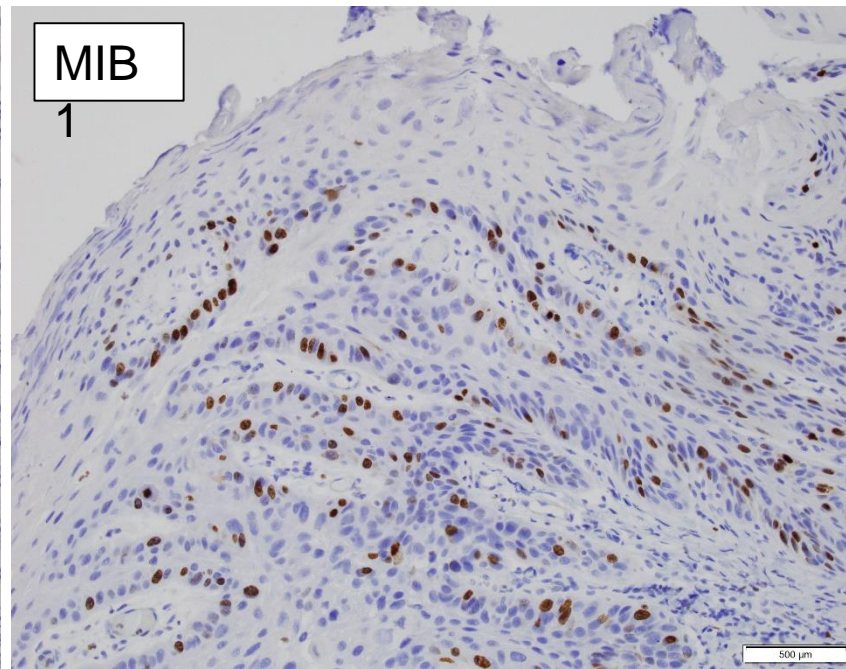
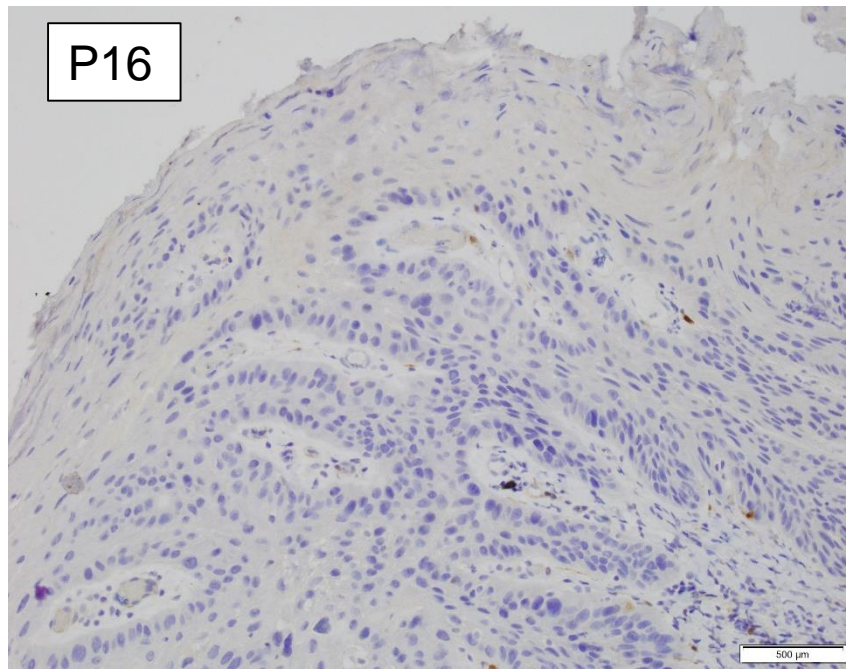
500  $\mu$ m

Subtle but abnormal maturation in all levels

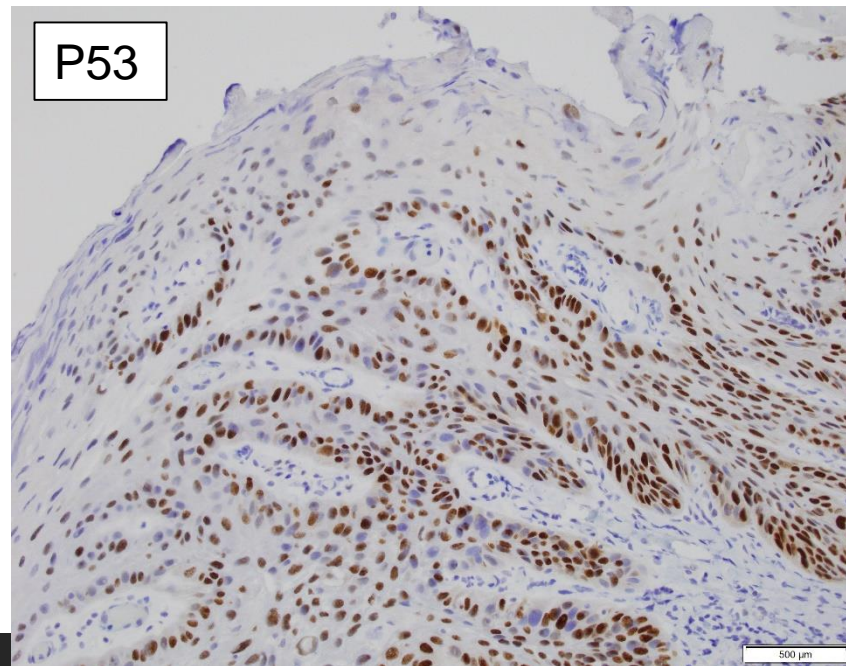
Nuclear enlargement, hyperchromatic nuclei,  
prominent nucleoli in basal layer

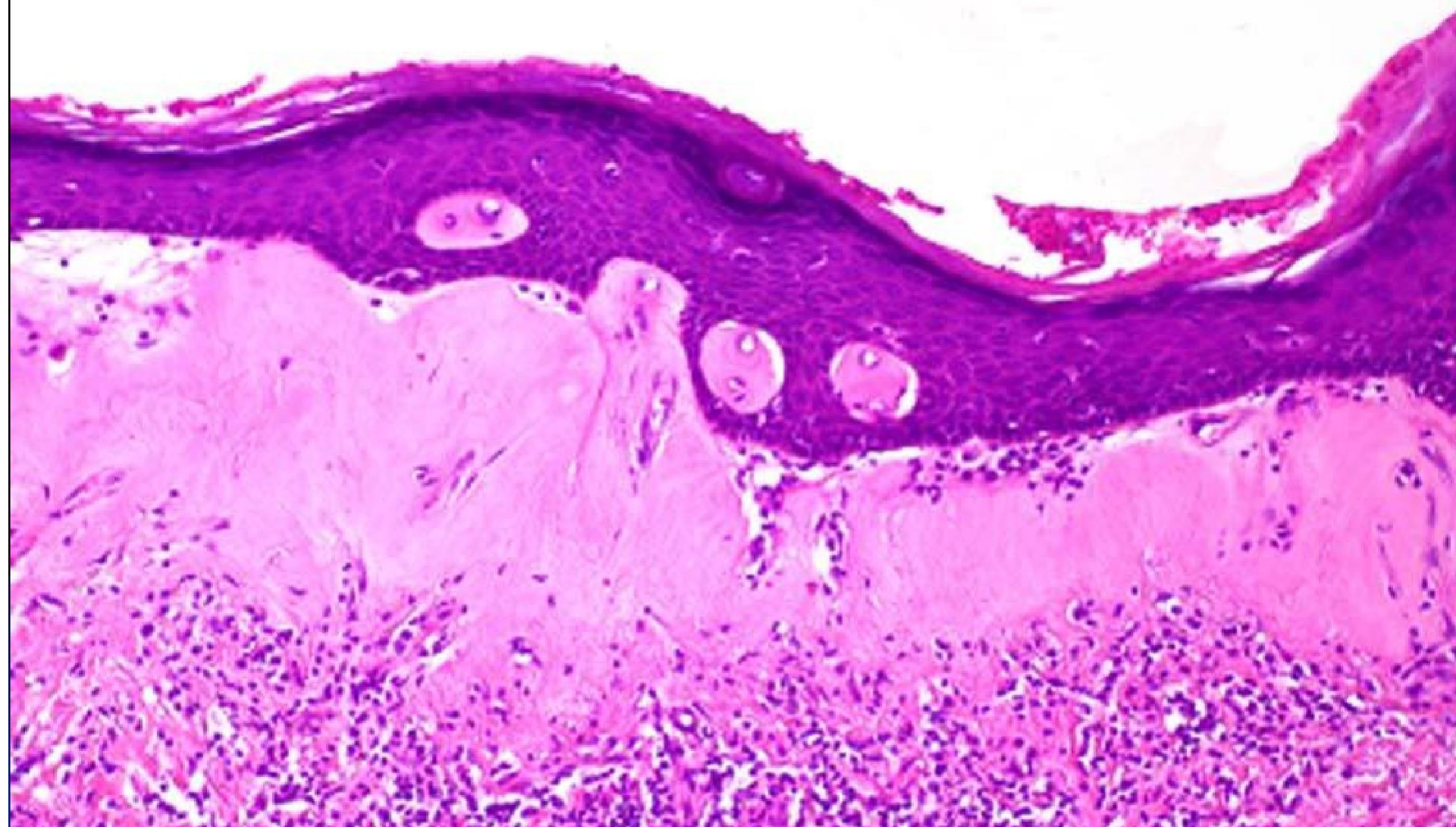
Spectrum of changes





## Differentiated PeIN





**Figure 3** Penile lichen sclerosus. There is thinning of the epidermis with hyperkeratosis and dense subepidermal hyalinisation. There is a band-like lymphocytic infiltrate deep within the dermis.

# Undifferentiated PeIN (Basaloid type)

45 year old male with erythematous lesion on the glans of the penis.

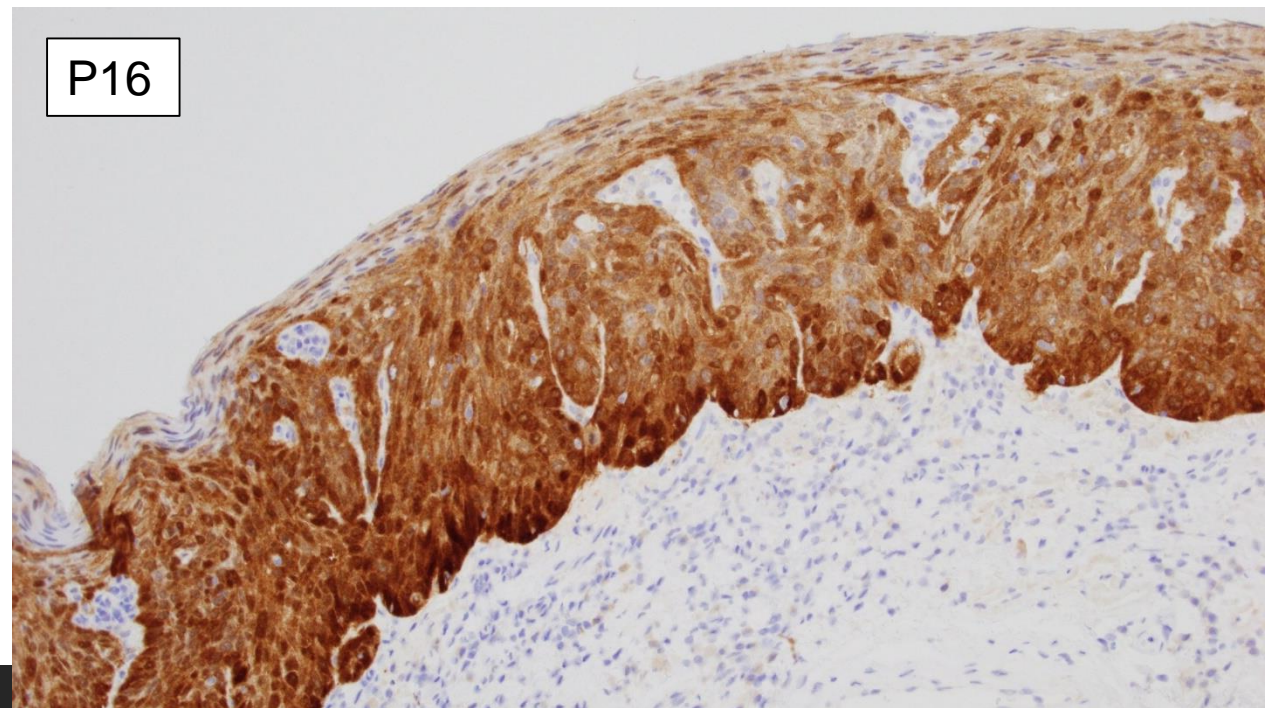
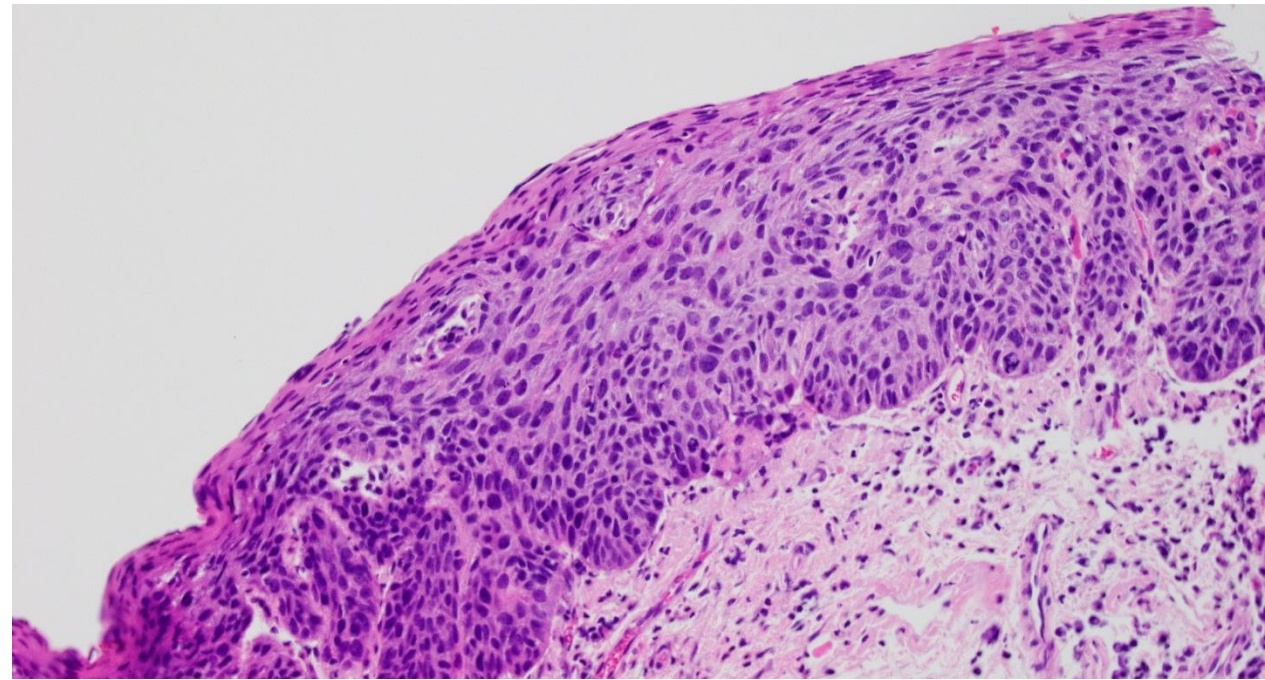
Full replacement of the squamous epithelium.

Immature small monotonous basophilic cells with round to oval nuclei.

Scant cytoplasm

Apoptosis and mitotic figures

HPV: Positive for genotype 16





# PENILE INTRAEPITHELIAL NEOPLASIA (PeIN)

---

- Alteration of the penile squamous epithelium characterized by dysplastic changes with an intact basement membrane.
- Precursor lesion of invasive squamous cell carcinoma.
- Unlike other organ sites this is not graded on the degree of dysplasia.
- In 2016, the World Health Organization (WHO) reclassified PeIN to incorporate two separate pathways of penile carcinogenesis based on the relationship with HPV.
- This classification also applies to invasive penile SCC.

PeIN does not need to be graded and is regarded as high grade by definition (agreed at ISUP/USCAP consensus meeting 2015)

- Erythroplasia of Queyrat (glans)
- Bowen's disease (shaft)
- Bowenoid papulosis
- Dysplasia (Mild, moderate, and severe)
- Carcinoma in situ
- Squamous intraepithelial lesion (SIL); low and high grade
- Penile intraepithelial neoplasia (PeIN 1, 2, 3)

**Table 5.03** Pathological classification of penile intraepithelial neoplasia (PeIN)

1. Non-HPV-related PeIN
  - Differentiated (simplex) PeIN
2. HPV-related PeIN
  - Basaloid PeIN
  - Warty PeIN
  - Warty-basaloid PeIN
3. Other rare patterns of PeIN
  - Pleomorphic
  - Spindle
  - Clear cell
  - Pagetoid

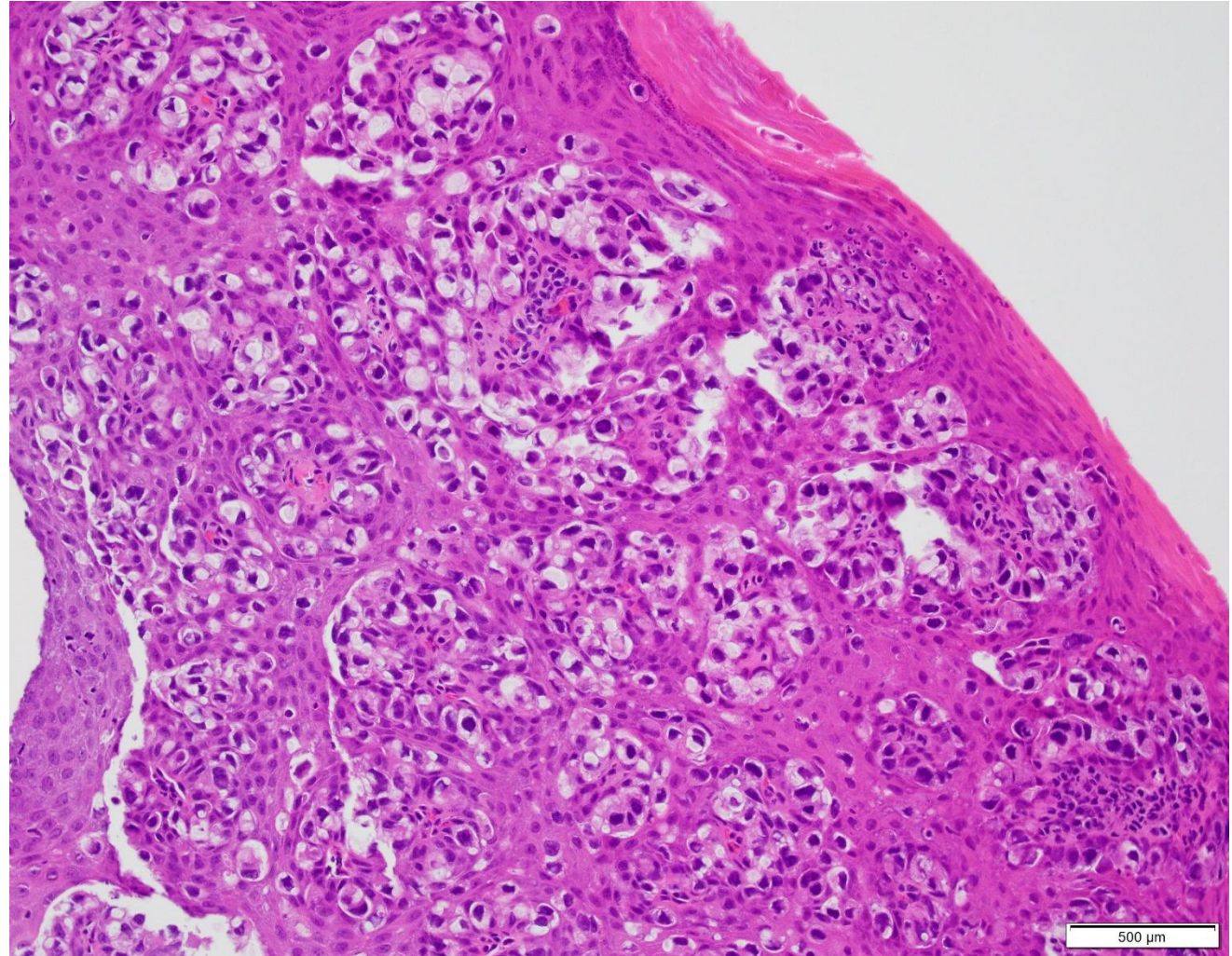
	Differentiated PeIN	Undifferentiated PeIN
Age (years)	>60	40-50
Location	Foreskin	Glans
Color	White/gray	Red
Multifocal	Sometimes	Often
HPV-related	No	Yes
p16	Negative	Positive
LS	Yes	No
Associated SCC	Usual Verrucous Sarcomatoid	Warty Basaloid Warty-Basaloid

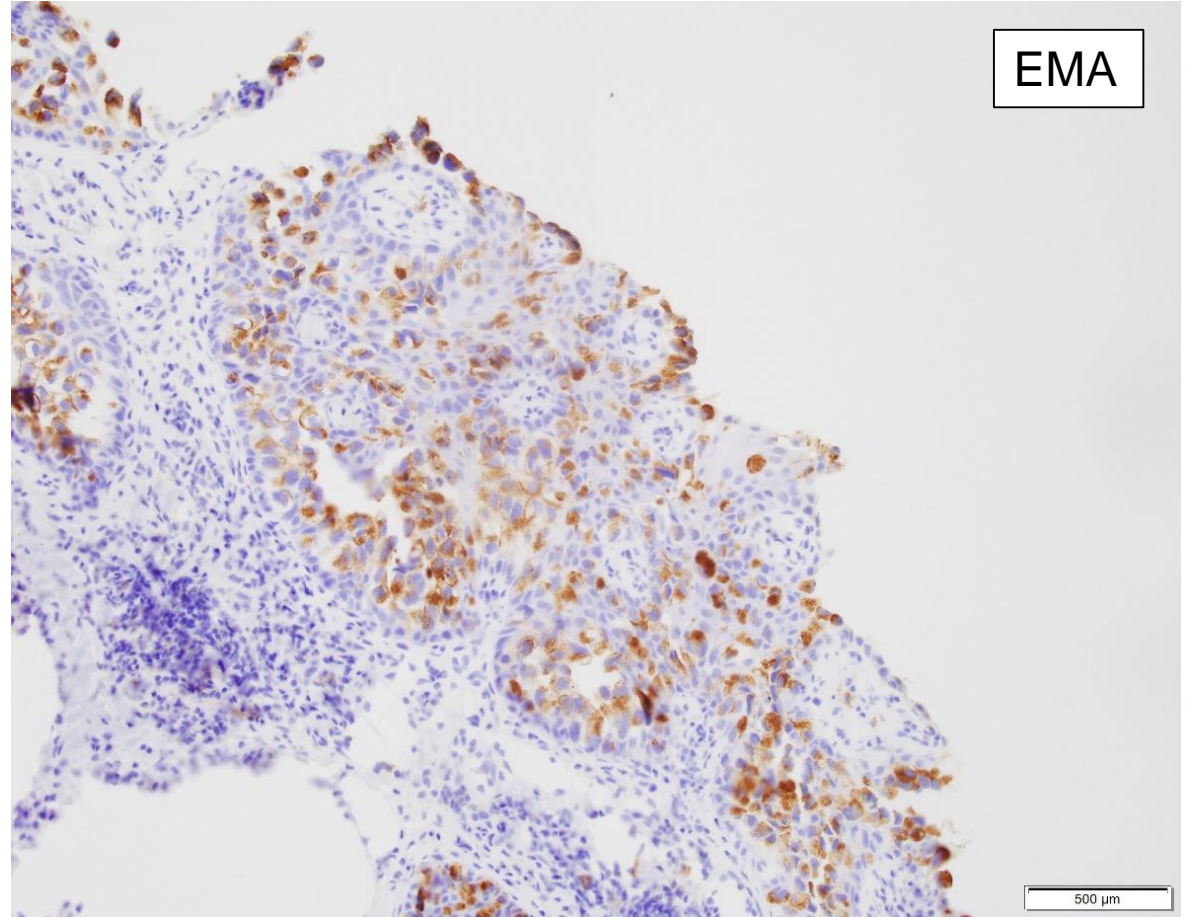
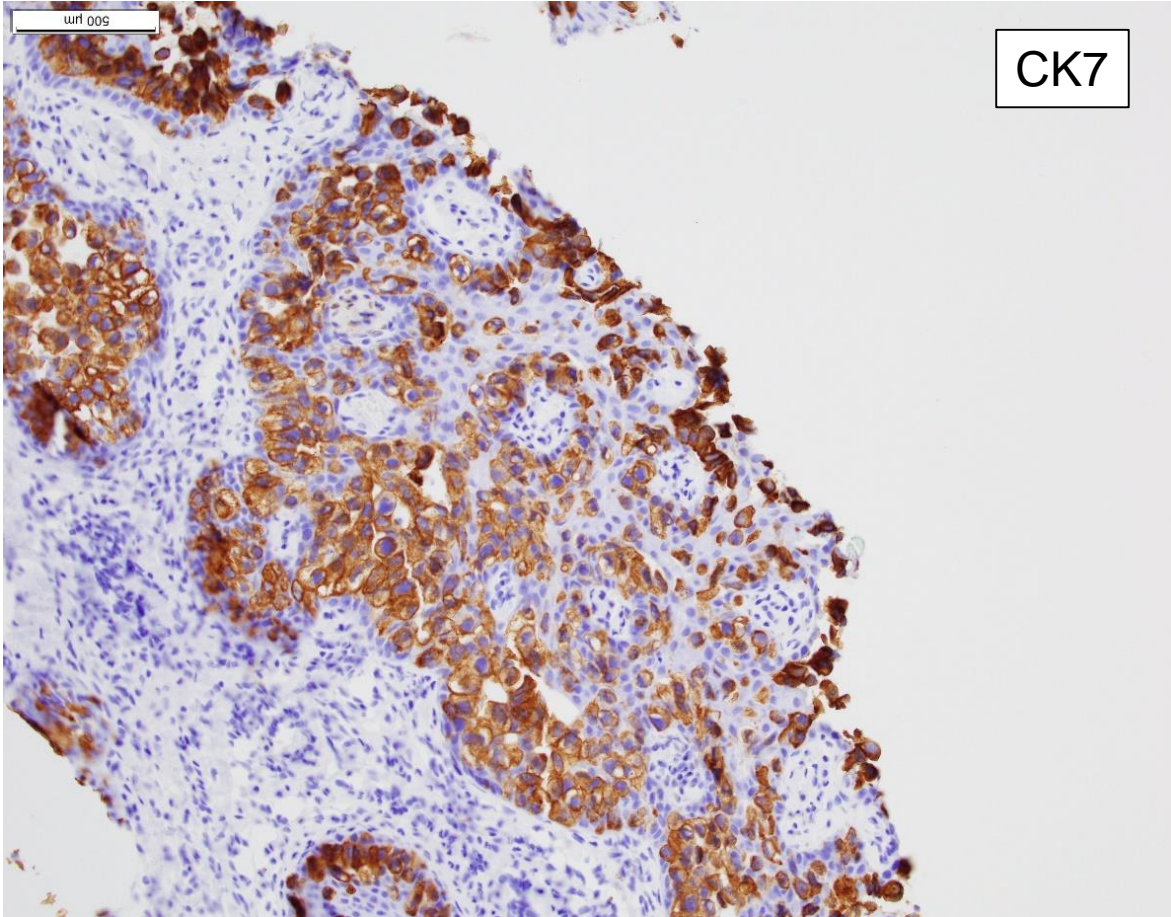
	<b>P16</b>	<b>P53</b>	<b>Ki67</b>
Squamous Hyperplasia	Negative	Negative	Variable
Differentiated PeIN	Negative	Variable	Positive (cells above basal layer)
Undifferentiated PeIN	Positive	Variable	Positive (full thickness)

# Extramammary Paget Disease

Non-invasive intraepithelial adenocarcinoma affecting the penile skin or mucosal surface.

Proliferation of large atypical cells with abundant pale cytoplasm and vesicular nuclei with prominent nucleoli that may form glandular lumina and may extend down the epithelium of adnexal structures.





- The neoplastic cells in primary extramammary Paget disease are positive for carcinoembryonic antigen (CEA), low-molecular weight cytokeratins (particularly CK7 and CAM5.2), epithelial membrane antigen, MUC1, and GCDFP15, and negative for CK20, p63, and CDX2.
- The phenotype of secondary Paget disease is variable, depending upon the nature of the underlying carcinoma
  - Rectal adenocarcinoma is CK7 variable, CK20+, CDX2+, CEA+, p63-
  - Urothelial carcinoma is usually CK7+, CK20+, Uroplakin III+, P63+, CDX2-, CEA-

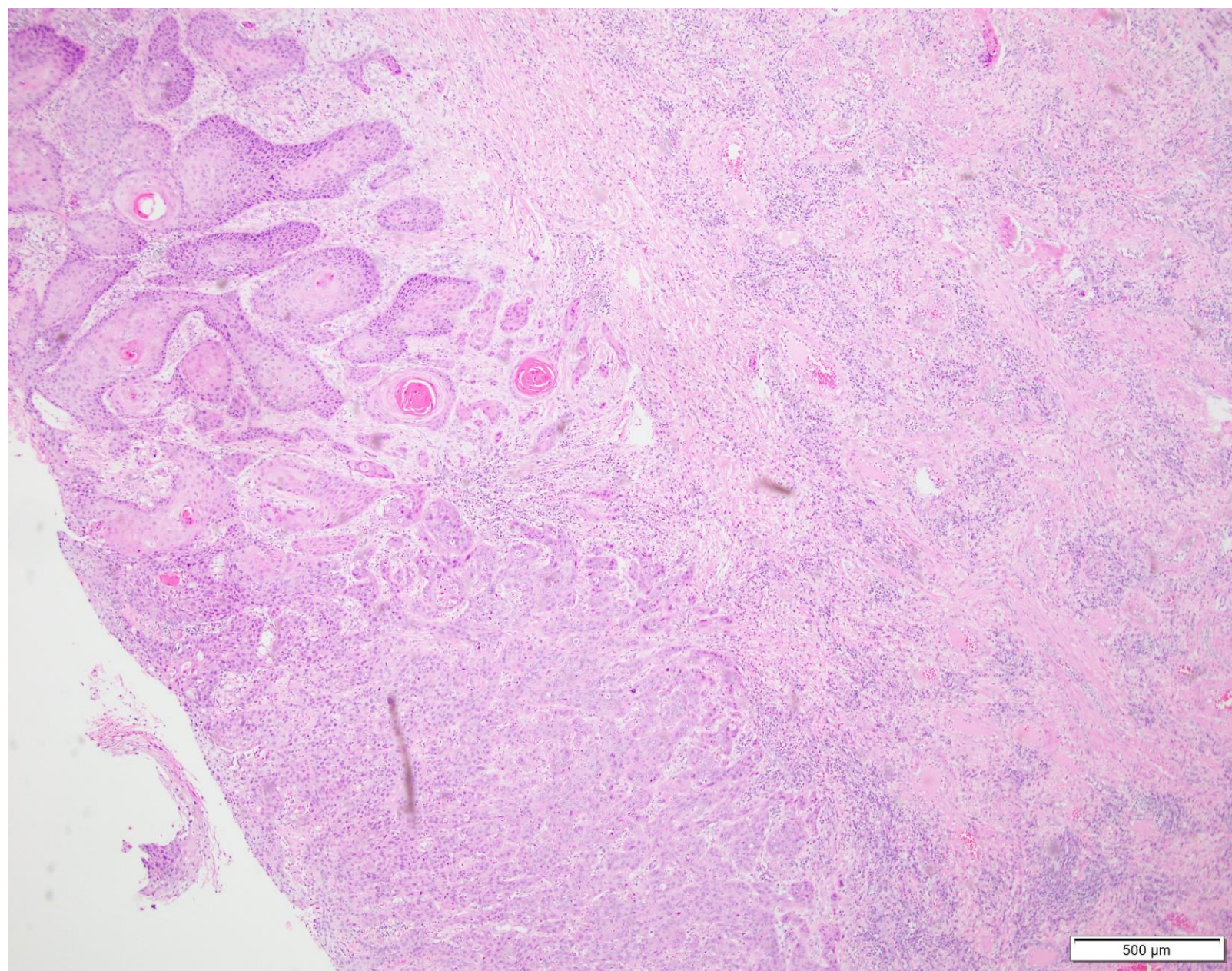


**Table 5.01** Pathological classification of penile squamous cell carcinoma (SCC)

<b>A. Non-HPV-related penile SCCs</b>
1. SCC Usual carcinoma Pseudohyperplastic carcinoma Pseudoglandular carcinoma
2. Verrucous carcinoma Pure verrucous carcinoma Carcinoma cuniculatum
3. Papillary carcinoma, NOS
4. Adenosquamous carcinoma
5. Sarcomatoid squamous carcinoma
6. Mixed carcinoma
<b>B. HPV-related penile SCCs</b>
7. Basaloid carcinoma Papillary-basaloid carcinoma
8. Warty carcinoma Warty-basaloid carcinoma Clear cell carcinoma
9. Lymphoepithelioma-like carcinoma
<b>C. Other rare carcinomas</b>

# Conventional SCC

- Invasive epithelial neoplasm with various degrees of squamous differentiation and keratinization
- Grade is an important prognostic factor and predicts inguinal lymph node metastasis
- Three tiered WHO/ISUP grading system should be used

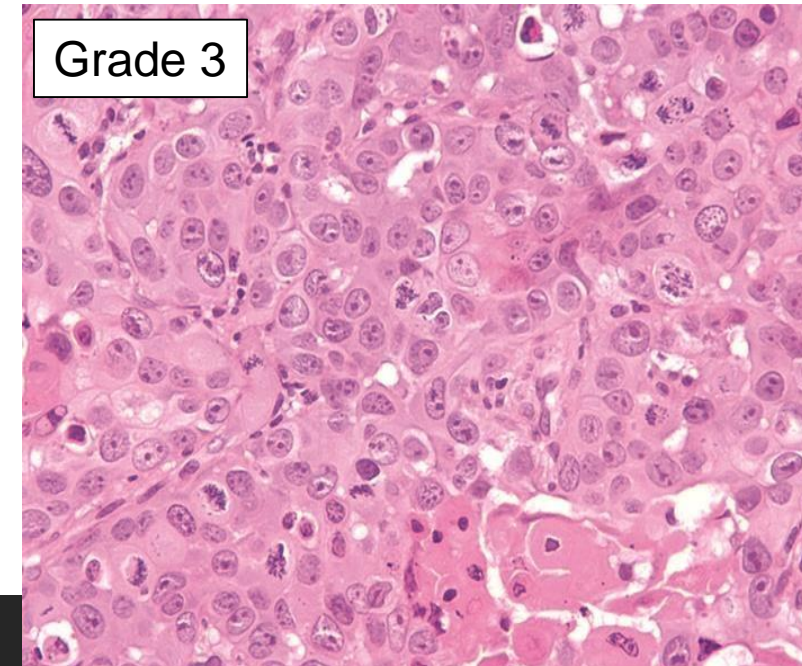
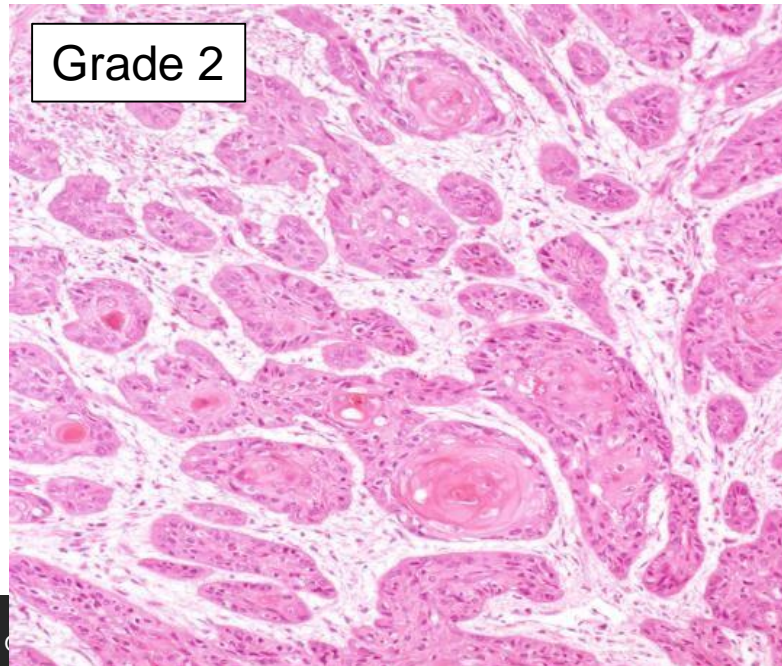
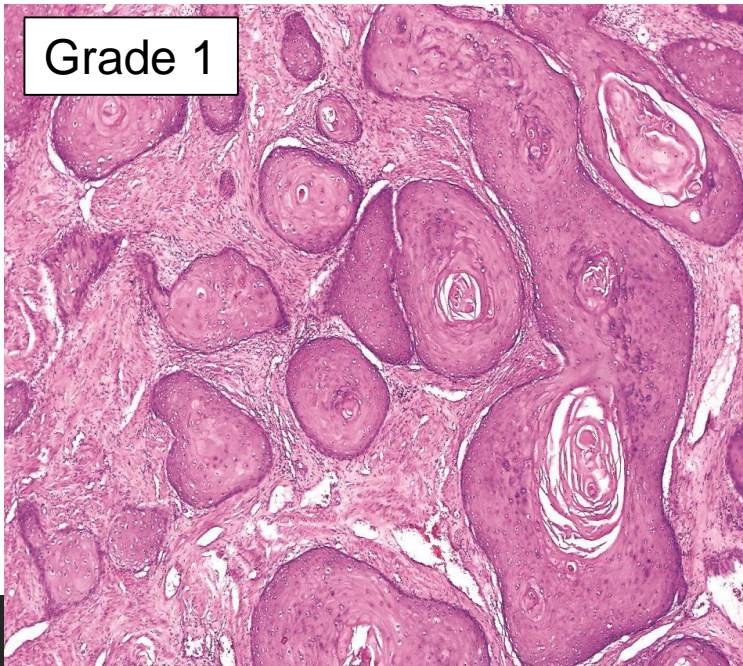


## E. Histologic Grade

Histological grade has been consistently reported as an influential predictive factor of groin metastasis and dissemination of penile cancer.<sup>20-22</sup> We recommend a method to grade penile SCCs as follows:

- Grade 1 is an extremely well-differentiated carcinoma, with a minimal deviation from the morphology of normal/hyperplastic squamous epithelium.
- Grade 2 tumors show a more disorganized growth as compared to grade 1 lesions, higher nuclear-to-cytoplasmic ratio, evident mitoses, and, although present, less prominent keratinization.
- Grade 3 are tumors showing any proportion of anaplastic cells, identified as solid sheets or irregular small aggregates, cords or nests of cells with little or no keratinization, high nuclear-to-cytoplasmic ratio, thick nuclear membranes, nuclear pleomorphism, clumped chromatin, prominent nucleoli, and numerous mitosis.<sup>22-23</sup>

A tumor should be graded according to the least differentiated component. Any proportion of grade 3 should be noted in the report.<sup>23</sup>

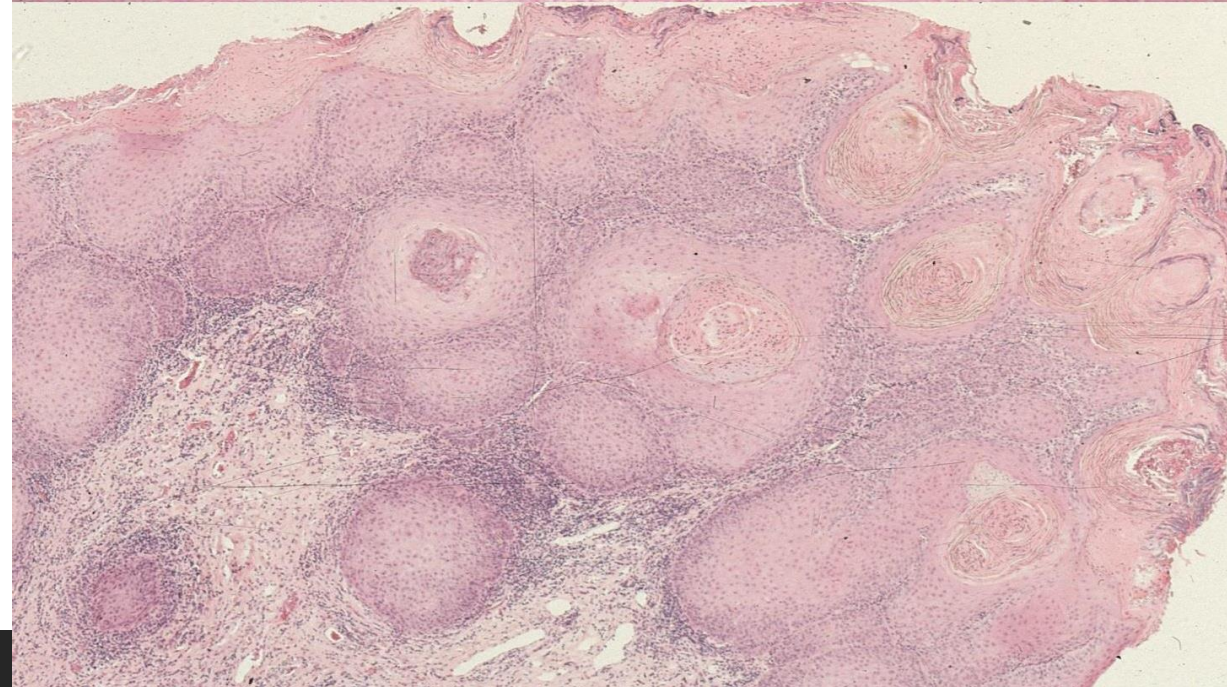
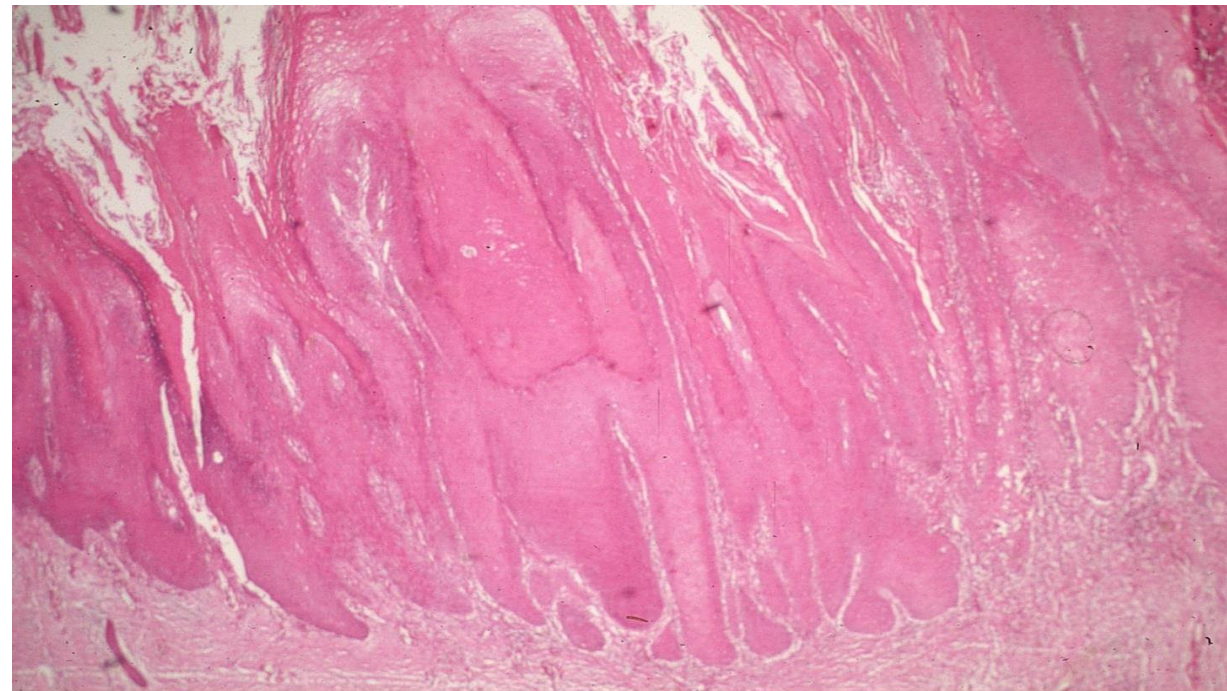


## Primary Tumor (pT)

- \_\_\_ pTX: Primary tumor cannot be assessed
- \_\_\_ pT0: No evidence of primary tumor
- \_\_\_ pTis: Carcinoma *in situ* (penile intraepithelial neoplasia [PeIN])
- \_\_\_ pTa: Noninvasive localized squamous cell carcinoma
- \_\_\_ pT1: Glans: Tumor invades lamina propria  
Foreskin: Tumor invades dermis, lamina propria, or dartos fascia  
Shaft: Tumor invades connective tissue between epidermis and corpora regardless of location  
All sites with or without lymphovascular invasion or perineural invasion and is or is not high grade
- \_\_\_ pT1a: Tumor is without lymphovascular invasion or perineural invasion and is not high grade (ie, grade 3 or sarcomatoid)
- \_\_\_ pT1b: Tumor exhibits lymphovascular invasion and/or perineural invasion or is high grade (ie, grade 3 or sarcomatoid)
- \_\_\_ pT2: Tumor invades into corpus spongiosum (either glans or ventral shaft) with or without urethral invasion
- \_\_\_ pT3: Tumor invades into corpora cavernosum (including tunica albuginea) with or without urethral invasion
- \_\_\_ pT4: Tumor invades into adjacent structures (ie, scrotum, prostate, pubic bone)

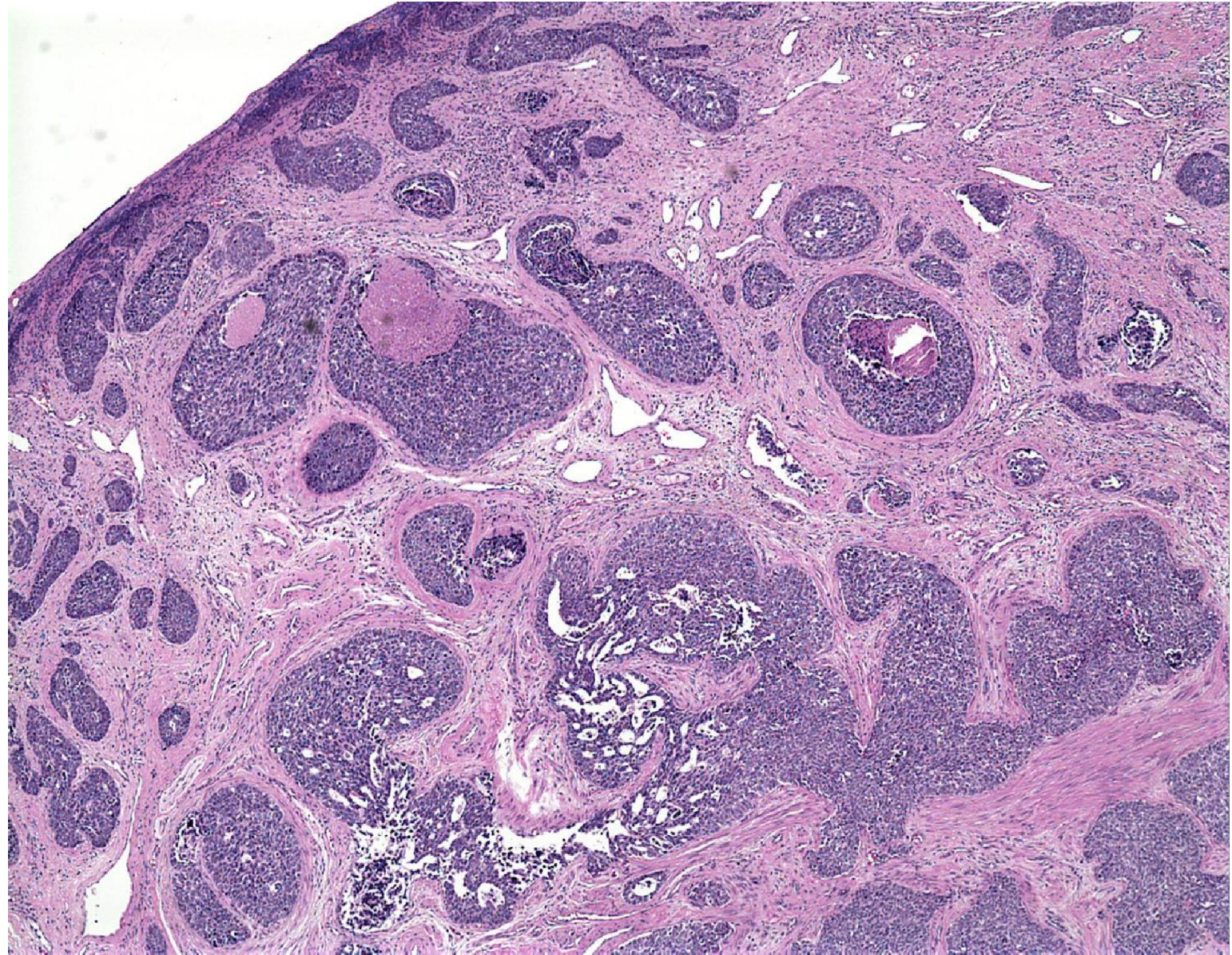
# Verrucous Carcinoma

- Always well differentiated and slow growing
- Associated with differentiated PeIN and LS
- P16 negative
- Does not metastasize. May recur locally
- Hyper-orthokeratosis, papillomatosis, and acanthosis. Church-spire appearance.
- The tumor front is broad based and pushes rather than infiltrates (making diagnosis of invasion difficult in small biopsies)
- Good prognosis unless mixed with conventional SCC
- Carcinoma cuniculatum variant looks similar but with areas of keratin filled cysts and sinuses



# Basaloid SCC

- Aggressive high grade tumor
- 50% have nodal mets at the time of presentation
- Basaloid cells with abrupt comedo necrosis/keratinization
- Associated with undifferentiated PeIN (Warty/Basaloid features)
- Associated with HPV 16 and 18, but not Lichen sclerosis
- P16 positive
- Vascular invasion often present



# Take home point

- PeIN does not need to be graded and is regarded as high grade by definition.
- In 2016, the World Health Organization (WHO) reclassified PeIN to incorporate two separate pathways of penile carcinogenesis based on the relationship with HPV.
- This classification also applies to invasive penile SCC.



**EMORY**  
UNIVERSITY  
SCHOOL OF  
MEDICINE

**Department of  
Pathology and  
Laboratory  
Medicine**



Georgia Association of Pathology

EMORY

.....

# 2020 Virtual Pathology Course

**FAISAL SAEED, MD**

**GENITOURINARY  
PATHOLOGIST**

**ASSISTANT PROFESSOR**