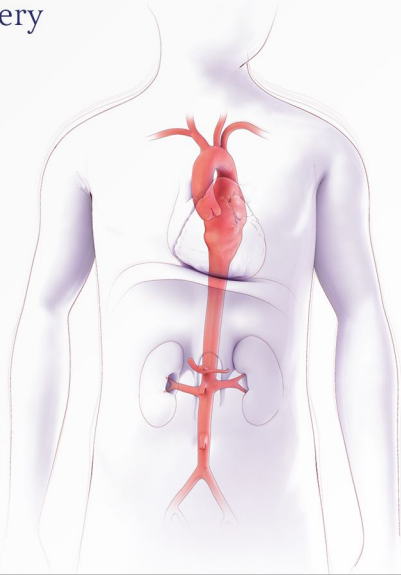
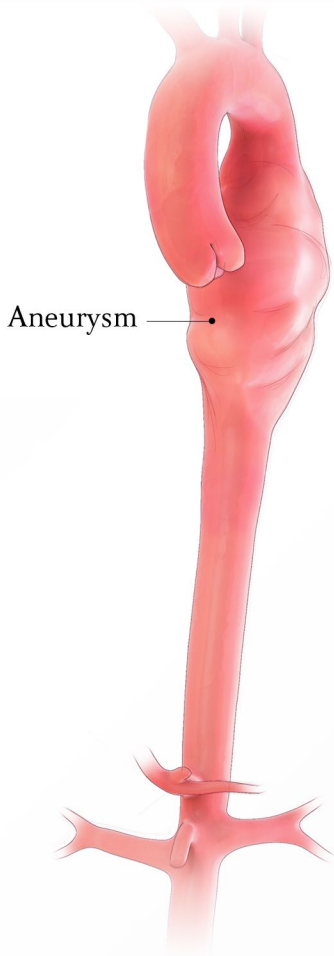


Descending Aortic Stent Graft (TEVAR) - Extent A

Before surgery



Close-up of diseased aorta



After surgery

