

# Radioembolization of Liver Tumors With Yttrium-90 Microspheres

Hojjat Ahmadzadehfar, MD, Hans-Jürgen Biersack, MD, PhD, and Samer Ezziddin, MD

Radioembolization (RE), also termed selective internal radiation therapy (SIRT), has been gradually introduced to the clinical arsenal of cytoreductive modalities in recent years. There is growing evidence for efficiency in liver tumors of various entities, with the most prominent ones being hepatocellular carcinoma, colorectal cancer, and neuroendocrine tumors. Hepatic metastases of numerous other tumor entities including breast cancer, cholangiocarcinoma, and pancreatic cancer are treatment-sensitive, even when being refractory to other treatment modalities such as bland-embolization, regional, or systemic chemotherapy. The antitumor effect of SIRT is related to radiation rather than embolization, with extraordinary high local radiation doses obtained selectively at the site of viable tumor and little affection of the surrounding normal liver tissue. Morphologic changes after RE may pose difficulties for interpretation in conventional restaging with regard to tumor viability and true response to treatment. Therefore, functional imaging, that is, metabolic imaging with  $^{18}\text{F}$  fluorodeoxyglucose positron emission tomography (computed tomography) in the majority of treated tumors, is regarded the gold standard in this respect and should be included for pre- and post-SIRT assessment. To prevent serious toxicity to be associated with the potent antitumor efficacy, meticulous pretreatment evaluation is of particular importance. Improvements in predicting dosimetry will help optimize treatment and patient selection. Nuclear medicine procedures are essential for planning, performing, and monitoring of RE. However, the interdisciplinary aspect of patient management has to be emphasized for this particular treatment form. As SIRT is moving forward from the salvage setting indication to the use in earlier stages of hepatic tumor disease and with the advent of new treatment protocols and targeted therapies, embedding SIRT into a multidisciplinary approach will become even more important. This article focuses on procedural and technical aspects for selection, preparation, and performance of treatment as well as post-therapeutic monitoring and response assessment.

Semin Nucl Med 40:105-121 © 2010 Elsevier Inc. All rights reserved.

The liver is a predominant site of metastasis from a wide variety of neoplasms, and 60%-80% of patients with a history of colorectal carcinoma, pancreatic carcinoma, breast cancer, and other tumor types will develop liver metastases.<sup>1</sup> In addition, the liver is at risk for the development of primary liver cancer, namely, hepatocellular and cholangiocellular carcinoma. Mortality and morbidity in patients with primary and metastatic liver cancer are directly related to the presence of hepatic disease. As an essential organ of metabolism and regulation, hepatic tumor involvement will play a critical role

for survival and quality of life, and therapeutic measures are aimed at tumor control in this organ.

Surgical resection of primary or metastatic liver cancer in patients with no evidence of disseminated disease, with or without adjuvant chemotherapy, is the most effective method for enhancing survival; however, hepatic malignancies in the majority of patients will be unresectable both at initial manifestation and at recurrence.<sup>2</sup>

Along with the significant progress in hepatobiliary surgery in the last 30 years, a number of innovative liver-directed treatments have been developed,<sup>3</sup> including conformal radiation, hepatic arterial infusion chemotherapy (HAI), transarterial chemoembolization (TACE), radiofrequency ablation (RFA), and radioembolization (RE) with yttrium-90 (Y-90) microspheres.<sup>4</sup>

Radiation is tumoricidal if sufficient doses can be delivered selectively to the tumor without damaging adjacent normal

Department of Nuclear Medicine, University Hospital Bonn, Bonn, Germany.

Address reprint requests to Samer Ezziddin, MD, Department of Nuclear Medicine, University Hospital Bonn, Sigmund-Freud-Str. 25, D-53127 Bonn, Germany. E-mail: samer.ezziddin@ukb.uni-bonn.de

tissue. Normal hepatocytes have a lower tolerance to the effects of radiation than neoplastic tissue. The dose required to destroy solid tumors, estimated at  $\geq 70$  Gy, is far greater than the liver tolerance dose of 35 Gy, when delivered to the whole liver in 1.8 Gy/d fractions.<sup>5</sup> If the whole liver is exposed to external-beam radiation at a mean radiation dose of 43 Gy, more than 50% of patients develop liver dysfunction.<sup>6</sup>

Conformal and stereotactic radiation therapy techniques can be used to deliver much higher radiation doses in cases with focal involvement;<sup>7</sup> however, since hepatic metastases and primary neoplasms are often multifocal and irregular in shape as well as potentially replacing large parts of the liver volume, only a minority of patients are optimal candidates for such therapies.<sup>8</sup>

RE, also named selective internal radiation therapy (SIRT), is a promising catheter-based liver-directed modality approved by the Food and Drug Administration (FDA) for patients with primary and metastatic liver cancer. SIRT provides several advantages over traditional treatment methods because of its low toxicity profile.<sup>1,9</sup> Its rationale arises from the anatomic and physiological aspects of hepatic tumors being exploited for the delivery of therapeutic agents. The prominent feature is the dual blood supply of liver tissue, from the hepatic artery and the portal vein. Observations on vascular supply to hepatic malignancies have demonstrated that metastatic hepatic tumors  $> 3$  mm derive 80%-100% of their blood supply from the arterial rather than the portal hepatic circulation.<sup>10</sup> This is in contrast to the normal liver tissue, which is predominantly fed by the portal vein (60%-70%).

## Physical Characteristics of Y-90 and Microspheres

Y-90 is a pure  $\beta$  emitter, produced by neutron bombardment of yttrium-89 in a reactor, with a limited tissue penetration (mean, 2.5 mm; max, 11 mm), and short half-life (64 h), making it an ideal transarterial liver-directed agent. The size of the microspheres ranges between 20 and 40  $\mu\text{m}$ . The upper size limit of the microspheres enables delivery to the tumors via the hepatic artery, whereas the lower size limit prevents the microspheres from passing from the arterial circulation into the venous circulation. The microspheres remain trapped within the vasculature of the tumors where they deliver a selective radiation dose to the tumor tissue.

The microspheres will not be degraded and will remain permanently implanted.<sup>11</sup> The mean tissue penetration of 2.5 mm leads to predominant radiation from the selectively delivered yttrium to the tumor tissue while sparing normal liver parenchyma. Because of this, SIRT can provide extremely high local tumor doses ranging from 50-150 Gy<sup>12-15</sup> to  $> 1000$  Gy, in contrast to the traditional whole-liver external beam radiation where radiation doses have to be limited to 30 Gy to prevent serious hepatic dysfunction, as discussed earlier.<sup>16</sup>

Two Y-90 microsphere products are commercially available: TheraSphere (glass microspheres) was approved in

**Table 1** Properties of Resin and Glass Yttrium-90 Microspheres

Y-90		
Microspheres	SIR-Spheres	TheraSphere
Company	Sirtex Medical, Sydney, Australia	MDS Nordion, Ottawa, Ontario, Canada
Material	Resin-based	Glass-based
Diameter	20-60 $\mu\text{m}$	20-30 $\mu\text{m}$
Activity per particle	50 Bq	2500 Bq
Number of microspheres per 3-GBq vial	40-80 $\times 10^6$	1.2 $\times 10^6$
Specific gravity	1.6 g/mL	3.2 g/mL
Maximal prescribed dose (GBq)	3	20
Relative embolic potential	High	Low
Relative pressure for infusion	Low	High
Contrast injection during infusion	Possible	Not possible

1999 by the US FDA for the treatment of unresectable hepatocellular carcinoma (HCC). SIR-spheres (resin microspheres) were granted full premarketing approval in 2002 by the FDA for the treatment of colorectal metastases in conjunction with intrahepatic fluorodeoxyuridine.<sup>5</sup> There are some distinct differences in properties between the 2 products as shown in Table 1.

## Patient Evaluation and Work-up

SIRT serves as an outstanding example for multidisciplinary management, including patient selection and care, detailed anatomical study, and dose calculation, the postinterventional treatment including timing and selection of systemic treatment, adequate follow-up of the patient as well as the management of possible complications. For each patient, certain steps have to be performed as detailed in the following paragraphs: clinical evaluation, appropriate imaging, pretreatment angiogram with selective visceral catheterization, and treatment simulation with Tc-99m labeled macroaggregated albumin (Tc-MAA), dose calculation, therapy, and follow-up.

### Clinical Evaluation

The selection process of patients referred for SIRT involves several aspects to be taken into account. Patients considered for SIRT should have unresectable hepatic primary or metastatic cancer, liver-dominant tumor burden, and a life expectancy of at least 3 months.<sup>5</sup>

Contraindications for SIRT include pretreatment angiogram indications of flow to the gastrointestinal tract—such as those visualized by the pretreatment Tc-MAA scan—which cannot be corrected by catheter embolization techniques, an

**Table 2 Basic Requirements for Radioembolization**


---

<b>Absent surgical (resection, liver transplantation) or ablative options (RFA)</b>
<b>Absent other conventional treatment option (chemotherapy, biotherapy)</b>
<b>Preserved liver function</b>
Bilirubin (<2 mg/dL)
Albumin ( $\geq 3$ mg/dL)
PT/PTT (no endogenous severe impairment)
CHE (no endogenous severe impairment)
AST/ALT $\leq 5 \times$ normal
<b>Adequate general condition (ECOG performance score <math>\leq 2</math>, KPS &gt;60%)</b>
<b>Liver-dominant tumor burden</b>
<b>Life expectancy <math>\geq 3</math> months</b>
<b>Acceptable LSF (<math>\leq 20\%</math> for resin and <math>\leq 30</math> Gy for glass microspheres)</b>

---

excessive shunting to the lungs as quantified by the Tc-MAA scan that would result in >30 Gy lung dose on a single administration, excessive tumor burden with limited hepatic reserve or biochemical evidence of reduced liver function as potentially indicated by elevated levels of bilirubin (widely suggested cut-off: 2 mg/dL), highly elevated liver enzymes (aspartate transaminase or alanine transaminase (ALT)  $> 5 \times$  upper normal limit), significantly altered international normalized ratio or partial thromboplastin time, or reduced serum albumin. Another issue is the compromised portal vein in bilobar disease, making the warranted whole liver (or sequential bilobar) treatment approach less feasible.<sup>5</sup> While minimally embolic treatment with glass microspheres may still be performed in these cases—Therasphere is indicated for patients with portal vein thrombosis (PVT) and has been shown to be safe even when the portal vein has been invaded by tumor; resin microspheres<sup>17</sup> will pose the patient at risk for significant liver dysfunction based on the embolic treatment effect. However, recent studies describe safe performance of SIRT with resin microspheres even in PVT. Patients with prior radiotherapy involving the liver should be carefully reviewed on a case-by-case basis (Table 2).<sup>1,5</sup>

The renal status should be adequate to accommodate any concurrent chemotherapy that is part of the treatment plan,<sup>11</sup> as well as for the use of contrast agents during the diagnostic and the therapeutic angiogram. Hemodialysis patients may be treated with SIRT; however, dialysis has to be planned and timed before and after the intervention.

One important aspect for patient selection before radioembolization is the general clinical condition, as described by the Eastern Cooperative Oncology Group (ECOG) or Karnofsky performance score. Patients with a significantly reduced performance status are at a higher risk of developing severe side effects, including radiation-induced liver failure.<sup>18,19</sup> Also, the outcome of these patients after treatment is worse, which leads to questioning the rationale of posing the patient at such costly and potentially harmful treatment measures. The minimal requirement for a patient undergoing SIRT should be an Eastern Cooperative Oncology Group (ECOG) score of  $\leq 2$ .

Biliary integrity with regard to potential ascending infections of the liver is another aspect for patient selection that has been emphasized by different groups. The so-called “violated ampulla,” as defined by a manipulation or removal of the natural barrier to ascending germs into the bile system, such as papillotomy, biliary stenting, or resection, may predispose for cholangitis and liver abscess formation in the follow-up period weeks or months after SIRT. Patients with recurrent infections of the bile system should be evaluated with special scrutiny before potential SIRT, as the intervention may be a substantial risk for increased infectious complications. However, as with all positive and negative predictors and risk factors of SIRT, potential hazards have to be weighed against the potential benefit and available treatment alternatives.

Portal hypertension should be viewed critically together with liver function and the proportion of liver involved by the tumor (segment, unilobar, bilobar). It is known that SIRT leads to an increase in portal pressure and deterioration of portal hypertension in the follow-up. If ascites is due to portal hypertension, the patient is at risk of increase in ascites. If ascites is tumor-related (exudative ascites), it is likely to show reduction or remission after SIRT. Ascites alone is not a contraindication to SIRT.

Regarding the patient medication at the time of evaluation, attention should be paid to antiangiogenic drugs, such as bevacizumab or sorafenib. These drugs should be discontinued in an adequate time frame before the pretreatment angiogram, for example, at least 2-4 weeks, in order to avoid vascular complications during the angiogram, such as dissection or rupture and bleeding, and optimize treatment efficiency at the later SIRT.

The decision to perform SIRT should be based on interdisciplinary consent, ideally after discussion in an adequate tumor board with participation of specialists in surgery, gastroenterology, oncology, radiology, nuclear medicine, and radiation therapy. Patients not fulfilling the common inclusion criteria should only be accepted as SIRT candidates after appropriate consent from such interdisciplinary tumor board.

Assessing the adequate tumor markers at baseline, depending on the tumor type treated, such as alpha-fetoprotein, carcinoembryonic antigen (CEA), carbohydrate antigen 19-9 (CA 19-9), chromogranin A (CgA) is recommended for later evaluation of treatment response during follow-up.

### Appropriate Imaging

First, it is crucial to assess and rule out relevant extrahepatic tumor spread. Since the effect of SIRT is exclusively confined to the liver and does not impact extrahepatic metastases, patients with extensive or prognostically relevant extrahepatic tumor spread should be treated by a systemic rather than a locoregional approach.

The work-up includes a three-phase contrast computed tomography (CT) and gadolinium-enhanced magnetic resonance imaging (MRI) of the liver for assessment of tumor and nontumor volume, portal vein patency, and extent of extra-

hepatic disease. For tumors with a high glucose metabolism rate whole-body  $^{18}\text{F}$  fluorodeoxyglucose positron emission tomography CT (FDG-PET/CT) can be also very helpful.<sup>5</sup> False-positive liver findings in FDG-PET are rare and primarily occur in inflammatory lesions, such as hepatic abscesses. Several studies have compared the accuracy of FDG-PET and CT in the detection of hepatic metastases.<sup>20-25</sup> Overall, FDG-PET was found to be more accurate than CT.<sup>20</sup>

Concerning the comparison with MRI,<sup>22,26</sup> there is no significant difference in the detection of liver metastases with gadolinium chelate-enhanced liver MRI and FDG-PET. Although FDG-PET might not be superior to CT or MRI in the detection of hepatic metastases, it surely adds to the decision-making and may have a great impact on the management of many patients due to its high sensitivity for intrahepatic and extrahepatic tumor burden.<sup>27</sup> Furthermore, follow-up and therapy-response assessment is more accurate if a metabolic imaging has been performed before the SIRT beside anatomical imaging modalities.<sup>28</sup> Although FDG-PET is suitable for tumors showing high glucose metabolism such as colorectal, melanoma, head and neck, and breast cancers, malignancies such as HCC or neuroendocrine tumors, except for their aggressive types show no or a very low-grade FDG uptake. The sensitivity of FDG-PET for the detection of HCC is sub-optimal, ranging between 50% and 70%.<sup>29,30</sup> Therefore, FDG-PET is not a satisfactory imaging choice for the pre- and post-treatment evaluation in this group of patients; however, it adds prognostic information (metabolic grading) as patients with a negative FDG-PET have a better prognosis than those with high FDG uptake. At the moment, somatostatin receptor scintigraphy (Octreoscan) and gallium-68-DOTA-TOC-PET/CT are regarded as the standard metabolic imaging tool in neuroendocrine tumors. Choline PET/CT may play a role in imaging of specific types of HCC in the near future.<sup>31-33</sup>

### Angiogram With Selective Visceral Catheterization and Therapy Simulation With $^{99\text{m}}\text{Tc}$ -MAA

Once a patient has been selected as a candidate for SIRT, an initial angiographic evaluation has to be performed as the first step. It is well known that the anatomy of the mesenteric system and the hepatic arterial bed has a high degree of variation, with "normal vascular anatomy" being present in 60% of cases. To perform any therapeutic transarterial procedure in the liver in a safe and efficient manner, one should be acquainted with the hepatic arterial anatomy.<sup>34</sup>

This is particularly important as dystopic spread of microspheres to other extrahepatic visceral sites such as stomach, duodenum, or pancreas, may be associated with the risk of severe radiation-damage leading to pain, ulceration and possibly perforation, pancreatitis, cholecystitis, skin necrosis, and other nontarget radiation complications.<sup>35</sup> Avoiding dystopic spread typically requires the embolization of vessels, such as the gastroduodenal, right gastric, pancreaticoduodenal branches, and the cystic artery, if applicable. Alternatively,

the catheter for treatment can be placed beyond the respective origins of these vessels.

A feature of the neoplastic vasculature within tumors is the formation of arteriovenous anastomoses or shunts. Shunts allow microspheres to directly enter the venous return by bypassing the terminal arterioles in the tumor. This will deposit the shunted microspheres into the lung, resulting in radiation pneumonitis.<sup>11,36</sup>

The angiogram must be accomplished with Tc-MAA injected into the hepatic artery similar to the application during microsphere treatment. The prophylactic embolization of all extrahepatic vessels at the time of Tc-MAA assessment is recommended to avoid extrahepatic deposition of microspheres. The angiographic techniques have been described in detail by Lewandowski et al.<sup>37</sup>

It has to be noted that these vessels/organs can revascularize quickly, and therefore the embolization should be performed close to the intended time of SIRT, with a check arteriogram required before SIRT to ensure that such revascularization has not occurred.<sup>5</sup>

Scintigraphy should be performed within 1 hour of injection of Tc-MAA to prevent false-positive extrahepatic activity due to free technetium. Due to free technetium, thyroid gland and often the stomach may be seen in Tc-MAA images, which usually seem confusing and a pathologic uptake in the stomach should be ruled out in such cases before the treatment. Since 2 years ago, all patients in our department have received 600 mg perchlorate per os 30 minutes before angiography to prevent "unspecific" uptake of Tc-99m-pertechnetate in the thyroid and stomach. Since then, we have not experienced any free technetium uptake in the stomach, affirmed also with single-photon emission computed tomography (SPECT)/CT.<sup>38</sup>

Determining possible lung damage due to liver-to-lung shunting is relatively simple, as described by Lau et al.<sup>39</sup> Following infusion of 200-400 MBq Tc-MAA in the hepatic arterial branches, a whole-body scan in anterior and posterior projections is sufficient to calculate the percentage of lung shunting and, consequently, the possibility of pulmonary side effects (Fig. 1). The percentage of lung shunting can be determined from the total counts within regions of interest over both lobes of the lung and the liver, using the geometrical mean of ventral and dorsal images. Depending on the shunt volume, a reduction in the total administered dose to the liver is necessary. Previous pre-clinical and clinical studies with Y-90 microspheres demonstrated the highest tolerable dose to the lungs to be up to 30 Gy with a single injection, and up to 50 Gy for multiple injections.<sup>36</sup> The estimated dose (Gy) to the lungs is equal to  $A \text{ (GBq)} \times \text{LSF} \times 50$ , assuming the total mass of both lungs to be 1 kg, where A is the activity infused and LSF is the lung shunt fraction. The cumulative absorbed lung radiation dose can be calculated with the following equation<sup>40,41</sup>:

Cumulative absorbed lung radiation dose

$$= 50 \times \text{lung mass} \sum_{i=1}^n A_i \times \text{LSF}_i$$

**Figure 1** Liver-lung shunt calculation following scintigraphy with Tc-99m-labeled macroaggregated albumin. The percentage of lung shunting can be determined from the total counts within the regions of interest over the lungs and the liver, using the geometrical means of the ventral and dorsal projections. (Color version of figure is available online.)

where  $A_i$  = activity infused,  $LSF_i$  = lung shunt fraction during infusion,  $n$  = number of infusions, and approximate vascular lung mass = 1 kg.

A more practical way is recommended by SIRTex Company. If the lung shunting is more than 10%, the amount of microspheres delivered to the patient is to be reduced or SIRT is even impossible if there is a shunt of more than 20% of the administered dose shown in Table 3.<sup>11</sup>

Detecting hot spots in other organs besides the liver with planar images is not always possible and problems arise when these 2-dimensional images are used for more precise evaluations. Extrahepatic accumulations indirectly mark the possible locations of microspheres misplaced during therapy; however, planar image analysis can be difficult and can lead to misinterpretation of possible extrahepatic locations because of the low spatial resolution of planar scintigraphic images. Furthermore, especially in the upper abdomen, the localization of several different organs within a relatively small region demands the analysis of tomographic images to accurately distinguish whether the Tc-MAA has accumulated in the liver or in some adjacent organ. Planar images cannot always make this distinction due to organ superposition. SPECT provides valuable additional information. This process can be improved by using SPECT/CT cameras, which avoids problems related to the time interval between different

studies, different positioning in different tomographs, and time-consuming software-based fusion as compared with hardware-based procedures.<sup>38,42</sup> In a study conducted in our department, extrahepatic accumulations were found in 42% of studies using SPECT/CT compared with only 12% and 17% in planar images and SPECT alone, respectively (Fig. 2).<sup>38</sup>

## Dose Calculation and Therapy Planning

Therapy planning includes definition of the target volume for the treatment and assuring the safety of the procedure discussed earlier. The combination of morphological imaging (CT and MRI) with functional imaging, preferably obtained using combined imaging modalities (PET/CT, SPECT/CT), provides the most reliable information for determining which parts of the liver need to be treated. Most importantly, the fusion of functional and morphological images allows the clinician to distinguish between active liver metastases and post-therapeutic changes occurring after cryotherapy, chemotherapy, or RFA. Depending on the distribution of the liver malignancies, either right, left, or both liver lobes should be treated. Sequential treatments may be safer than a whole liver treatment in 1 session. In the case of sequential treatments, a 30-45-day interval between the therapies is the generally accepted practice.<sup>18,19,43</sup> Depending on the angiographic situation, a superselective therapy of single vessel branches may be performed.

In addition to the selective distribution of the microspheres to the liver, the distribution within the liver plays a critical role. It should result in low radiation doses to normal liver tissue and a lethal dose (typically more than 120 Gy) to the tumor tissue. Abnormal high radiation doses to normal tissue may result in radiation-induced hepatitis with potential risk of liver failure.<sup>44</sup>

The required activity for treatment of each patient is to be calculated differently according to whether glass or resin microspheres are to be used and their significant physical differences should be considered (Table 1). Selection of the optimal activity of microspheres for an individual patient is a complex and challenging endeavor. Some methods for dose calculation are briefly introduced here.

### Glass Y-90 Microsphere Activity Calculation

TheraSphere consists of insoluble glass microspheres where Y-90 is an integral constituent of the glass. The mean sphere diameter ranges from 20 to 30  $\mu\text{m}$ . Each milligram contains 22,000-73,000 microspheres.<sup>45</sup>

**Table 3** The Percent Lung Shunting May Alter the Activity That Can Be Safely Implanted Commensurate With Acceptable Risk of Radiation Pneumonitis

Percent Lung Shunting	Activity of SIR-Spheres Microspheres
<10%	Deliver full amount of SIR-spheres
10%-15%	Reduce amount of SIR-spheres by 20%
15%-20%	Reduce amount of SIR-spheres by 40%
>20%	Do not give SIR-spheres microspheres

**Figure 2** Duodenal accumulation (white arrow) in a patient with colorectal cancer (CRC), not discernable in the planar scan. A second Tc-99m-labeled macroaggregated albumin examination performed after embolization of the suspected arteries for causing the duodenal tracer accumulation showed no longer abnormal extrahepatic tracer accumulation (not shown here). (A) planar scan, (B) single-photon emission computed tomography coronal view, (C) single-photon emission computed tomography/computed tomography (CT) coronal view, and (D) CT coronal view.

The dose determination for glass microspheres is based on a nominal average target dose (80-150 Gy/kg) and the patient's liver mass that is determined from the CT data and assumes the uniform distribution of the microsphere throughout liver volume as<sup>46</sup>:

$$A \text{ (GBq)}_{\text{glass}} = \frac{D(\text{Gy}) \times M(\text{kg})}{50}$$

In this equation, A is the activity, D the nominal target dose, and M is the mass of the targeted liver tissue.

For a typical patient with a liver mass of 2 kg, the required activity is 6 GBq to achieve 150 Gy to the target tissue. It is recommended that the cumulative lung dose be kept to <30 Gy to prevent radiation pneumonitis. The target dose for any given solid tumor is not known; however, it is believed that doses of 100-120 Gy balance response rates and hepatic fibrosis risk when glass microspheres are used.<sup>5</sup>

When lung shunt fraction and residual activity in the vial after treatment are taken into account, the actual dose delivered to the target mass (Gy) becomes:

$$D(\text{Gy}) = [A(\text{GBq}) \times 50 \times (1 - [\text{LSF} - R])]/M(\text{kg})$$

Where A is net activity delivered to the liver, D is the radiation absorbed dose to the target liver mass, M is target liver mass, LSF is lung shunt fraction, and R is percentage residual activity in the vial.<sup>19</sup>

#### Resin Y-90 Microsphere Activity Calculation

There are 2 methods for prescribed activity determination provided by the resin microsphere user's manual:<sup>11</sup> (1) the empiric method and (2) the partition method.

#### The Empiric Method

The empiric method recommends a standard amount of activity, which is adapted only according to the size of the tumor within the liver. The recommended activity to be implanted for varying degrees of tumor involvement of the liver is as follows:

- Tumor ≤25% of the total mass of the liver by CT scan = 2 GBq whole-liver delivery
- Tumor >25% but <50% of liver mass by CT scan = 2.5 GBq whole-liver delivery
- Tumor >50% of liver mass by CT scan = 3 GBq for whole-liver delivery

**The Body Surface Area Method.** Body surface area (BSA) method is a variant of the empiric method that is to adjust the activity implanted according to the size of the tumor within the liver and the size of the patient. The BSA method is calculated as follows:

First, BSA is calculated from a weight/height chart.

$$BSA(m^2) = 0.20247 \times \text{height}(m)^{0.725} \times \text{weight}(kg)^{0.425}$$

The activity of SIR-spheres can be calculated with the following formula:

Activity of SIR - Spheres in GBq = (BSA - 0.2)

$$+ \left[ \frac{\text{volume of tumour}}{\text{volume of tumor} + \text{volume of normal liver}} \right]$$

The BSA method is recommended for patients having concurrent systemic chemotherapy or for particularly small patients.<sup>11</sup>

## Medical Internal Radiation

### Dose Theory and the Partition Model

This method involves implanting the highest possible activity to the tumor while maintaining radiation dose to sensitive tissues, such as the lung and the normal liver. The partition model was developed from basic medical internal radiation dose (MIRD) methodology to provide an estimate of the radiation dose separately to tumor and normal liver. The partition model considers the liver and tumor to be effectively separate organs from the point of view of MIRD. This model relies on accurate information relating to the degree of lung shunting, liver mass, tumor mass, and tissue/normal ratio (T/N) ratio.

Use of the partition model requires 2 measurements to be made:

- measurement of the volume of tumor and normal liver determined from a CT scan and
- measurement of the proportion of Tc-MAA activity that lodges in the tumor, normal liver, and lung.

To determine the T/N, the following equation should be used:

$$T/N = \frac{(A_{\text{tumour}}/M_{\text{tumour}})}{A_{\text{liver}}/M_{\text{liver}}}$$

where

$A_{\text{Tumour}}$  is the activity in tumor

$M_{\text{Tumour}}$  is the mass of tumor

$A_{\text{Liver}}$  is the activity in the normal liver

$M_{\text{Liver}}$  is the mass of the normal liver

The activity could be calculated as shown by the equation below:

$$A(\text{GBq})_{\text{re sin}} = \frac{D_{\text{liver}}(\{T:N \times M_{\text{tumour}}\} + M_{\text{liver}})}{49670(1 - \text{LSF}/100)}$$

where

$D_{\text{liver}}$  = nominal dose (Gy) to the liver

$\text{LSF}$  = shunt fraction (%) of microspheres from liver to lung based on MAA scan

$M_{\text{liver}}$  = total mass of liver (kg) from CT volume

The partition model has been described in detail in the SIRT user manual.<sup>11</sup>

The activity prescribed can be reduced if the hepatic function is compromised. There are no accepted guidelines as to how much the activity should be reduced, if a patient's liver function or estimated reserve is only good enough to be a candidate. Generally, more experienced users reduce the dose by 30% for patients with poorer liver function, but who are still candidates for this approach according to established eligibility criteria.<sup>5</sup> The amount of yttrium-90 should also be reduced according to the dose adjustment of lung shunt (Table 3) if the percentage lung shunting is greater than 10%.<sup>47</sup>

## Therapy

For better tolerance of SIRT, some premedications are advisable.

### Gastrointestinal Ulcer Prophylaxis

Due to the possibility of small unrecognized arterial vessels coursing to the gastrointestinal system, the routine use of prophylactic antiulcer medications in all patients is recommended. A proton pump inhibitor (eg, omeprazole or pantoprazole), more effective than alternatives such as H2-blockers (eg, ranitidine), optimally commenced 1 week before SIRT and continued for at least 4 weeks post-treatment is advised.

### Antinausea Prophylaxis

Antiemetics (eg, ondansetron or granisetron) are recommended before and after SIRT to reduce post-treatment nausea. When glass microspheres are used, these medications are only needed on demand by symptoms, which are not expected due to the little embolic effect of treatment.

### Postembolization Syndrome Prophylaxis

Fever, malaise, and lethargy can occur because of the radiation injury and embolic effect of the SIRT on the tumor neovasculature. Oral corticosteroids (eg, dexamethasone 4 mg BID) are recommended for 3 days starting at the day of treatment. Additionally, intravenous high-dose steroids immediately before treatment are helpful for tolerance. Potential relative contraindications (diabetes) should be considered. The steroids are usually not needed when treating with glass microspheres due to the little-to-absent embolic effect.

### Pain Control

Oral analgesia may be required for 1 week following treatment to relieve pain from radiation injury and the embolic effect of microspheres, and liver capsular pain from tumor edema.<sup>11</sup>

Using slow infusion of an i.v. analgesia (eg, pethidine) and a corticosteroid during therapy with SIR-spheres could be helpful against embolization symptoms.

### Injection of the Calculated Dose

Calculated activity is injected after confirming that there are no new collateral vessels connecting to the gastrointestinal

tract. This confirmation is done merely by fluoroscopy through the interventional radiologist in the angiography suite, where the therapeutic infusion is also carried out. The catheter is usually positioned in essentially the same location as that used at arteriography for therapy planning. There are 2 different administration sets for the application of resin and glass microspheres. The preparation of these sets and the method of injection have been described in detail in the respective instructions manuals.<sup>11,40</sup>

During the application, direct tracking of microspheres distribution is not feasible and usually not required while using glass microspheres, but is mandatory when performed with resin microspheres because of the relatively high embolic tendency. In the latter case, the radiologist must repeatedly check with fluoroscopy to ensure that the resin microspheres are being delivered only to the liver and that reflux is not occurring back down the artery as this will result in spillage into other organs, such as the stomach and duodenum. It is of utmost importance to ensure that flow is adequate and forward, since change of flow—even with flow reversal—may occur at any time during treatment with resin microspheres.

Patients then remain in the hospital overnight, and supportive therapy consisted of a proton pump inhibitor, prescribed for at least 1 month, as well as antiemetics and analgesics are administered on demand. The groin incision should be observed for 24 hours for hematoma formation. The patient should be kept supine for 6 hours, with full mobilization after 24 hours. The patient can receive normal nutrition and fluids when tolerated immediately after the procedure.

Another issue is potential concurrent chemotherapy before and after SIRT. In some instances, chemotherapy may be paused, for example, 2-3 weeks before SIRT, to reduce the potential hazard to liver function, as in decreased pretreatment liver function and known radiosensitizers, such as 5-FU/capecitabine or gemcitabine. Such pausing schedules may decrease the risk of radiation-induced liver failure,<sup>8</sup> especially after whole liver treatment. However, treatment protocols using SIRT in conjunction with dose-adapted chemotherapy, such as folinic acid, fluorouracil, irinotecan (FOLFIRI) or folinic acid, fluorouracil, oxaliplatin (FOLFOX), have proved to be safe in different settings.

It is highly recommended to perform bremsstrahlung scintigraphy, up to 24 hours after application of the microspheres to document the distribution of microspheres within the liver. Accidental extrahepatic spread of microspheres can also be visualized on post-therapeutic images. In case of adverse events, this may enable faster diagnosis and early initiation of treatment. The acquisition of additional SPECT/CT images and the use of advanced reconstruction techniques like iterative reconstruction may further improve image quality, but due to strong bremsstrahlung attenuation, quantitative evaluation currently does not seem to be completely feasible, but may be so in the near future.<sup>48,49</sup>

### Complications and Side Effects

Overall, the incidence of complications after SIRT—if patients are selected appropriately and target delivery is per-

formed meticulously—is low.<sup>8</sup> They can be divided into extrahepatic and intrahepatic complications.

Apart from this, there is frequent observation of postembolization symptoms that are not addressed as complications. It is quite common for patients undergoing SIRT with resin microspheres to experience mild postembolization syndrome during the therapy, on the day of treatment and for up to 1-2 weeks after treatment. These symptoms include fatigue, nausea, and abdominal pain.<sup>5</sup> The most prominent aspect of postembolization syndrome is fatigue, occurring in over 50% of the patients undergoing SIRT with resin microspheres.

Fever does not necessarily indicate sepsis, but may be related to the embolic effect of the microspheres and the acute toxic effects on the tumor. If there is any suspicion of bacterial infection, it should be investigated and treated appropriately. Some patients experience nausea lasting up to several weeks, occasionally being severe enough to require antiemetic medication that should be continued until the symptoms subside. Many patients experience significant abdominal pain immediately after administration of SIR-spheres (resin microspheres) and may need pain relief with narcotic analgesia. The pain generally subsides within an hour, but patients may require oral analgesia for up to several days.<sup>11</sup>

### Extrahepatic Complications

Serious complications have been reported when microspheres were inadvertently deposited in excessive amounts in organs other than the liver. Reported conditions include gastrointestinal ulceration/bleeding, gastritis/duodenitis, cholecystitis, pancreatitis, and radiation pneumonitis.<sup>1,8,36,50-52</sup>

Delayed cases of gastroduodenal ulceration were observed, despite the contribution of experienced interventional radiologists and standard pretreatment evaluation.<sup>39</sup> These cases that would be associated with small amounts of Tc-MAA misplaced into the stomach and undetected by conventional scintigraphic planar images could have been avoided by the use of SPECT/CT (Fig. 2).<sup>38,42</sup> Our own preliminary experience with SPECT-CT shows that the use of this modality leads to a change of the treatment plan (eg, reangiogram with occlusion of additional vessels or therapeutic injection at a different catheter position) in about 26% of cases compared with the application of conventional imaging (planar + SPECT).

**Radiation Induced Pneumonitis.** Lung tissue is very sensitive to radiation. After intra-arterial injection of Y-90 microspheres into the liver, a small fraction of the radioactive substance is shunted into the lung via intrametastatic arteriovenous shunts.<sup>53</sup> If a large proportion of the injected radionuclide microspheres (>15%) is shunted into the lung, the risk of radiation-induced pneumonitis is increased.<sup>36</sup> The resulting dose to the lungs can be predicted by the Tc-MAA shunt fraction and the injected activity of the radiomicrospheres. A dose of, >30 Gy may lead to pulmonary toxicity. The symptoms indicating radiation pneumonitis include dry cough, progressive dyspnea, restrictive ventilation deficits resulting



in deteriorating lung function, and in the worst case even death 1 month after SIRT.<sup>36</sup>

**Gastrointestinal and Pancreatic Complications.** The microspheres may spread into the vascular territory of the gastrointestinal organs resulting in a severe damage of the gastrointestinal organs in less than 5% of therapies. Radiation as well as diminished blood supply due to embolization with the spheres and subsequent hypoxia may result in ulceration and even perforation of the stomach and duodenum.<sup>39,54</sup> 90Y-induced ulceration of the stomach or duodenum may be resistant to medical therapy requiring surgery.<sup>51</sup>

If microspheres spread into the vessels supplying the pancreas, radiation-induced pancreatitis may occur, most frequently affecting pancreatic head.

Organs adjacent to the liver may also receive radiation doses if microspheres are lodged on the periphery of the liver. The organ most likely affected by radiation from the liver is the gastrointestinal tract, and some radiation gastritis are expected in these patients.<sup>11,8</sup>

Overall training, careful patient selection, meticulous pretreatment assessment, and coiling of relevant vasculature reduce complication rates massively.<sup>55</sup>

### Intrahepatic Complications

One important complication is affection of the nontumorous hepatic parenchyma by radiation. Cases of veno-occlusive disease, radiation hepatitis, and hepatic fibrosis have been described. With the objective of adjusting the therapeutic doses as accurately as possible and avoiding the presence of liver complications, as far as possible, careful dosimetric studies should be carried out.

**Elevation of Liver Function Tests.** Transient elevation in liver function tests may occur in patients after SIRT, specifically a mild increase in ALT, alkaline phosphatase, and bilirubin.<sup>11</sup> As expected, the likelihood of toxicity is often related to the patient's pretreatment bilirubin level.<sup>8,19,43,56</sup>

**Radiation-induced Liver Disease.** This mechanism involves the irradiation of normal parenchyma beyond the tolerable dose (30 Gy).<sup>57</sup> Radiation-induced liver disease (RILD) is a rare complication of SIRT, since this technique enables safe delivery of radioactive particles to liver tumors, sparing healthy liver tissue, and induced 4-6 times higher tumor absorbed doses from 90Y-microsphere comparing those to the normal liver tissue.<sup>58,59</sup> Its incidence ranges from 0% to 4%.<sup>60,61</sup> It results in various degrees of hepatic decompensation and is indistinguishable from hepatic veno-occlusive disease.

RILD is manifested clinically by the development of anicteric ascites and increased abdominal girth, as well as rapid weight gain with hypoalbuminemia. The number of patients with jaundice is rare at presentation. Physical examination reveals ascites and hepatomegaly in moderate to severe cases; however, in mild cases these signs are detectable only by ultrasound or abdominal CT scan. Serum chemistries tend to show moderate elevations of aspartate transaminase and ALT (in the range of 2-fold above normal), minimal or no increase

in bilirubin, and a substantial increase in alkaline phosphatase (in the range of 3-10 times above normal). Clinical results are usually worse than histologic results.<sup>16,39</sup>

Multifactorial analyses indicated that RILD was associated with tumor volume of 70% or greater of the liver, increasing total bilirubin level, and delivered dose of 150 Gy or greater to the whole liver.<sup>56,60,62,63</sup>

Since radiation dose is related to liver toxicity, performing SIRT in a repeated, fractionated fashion is recommended to reduce the risk of liver toxicity,<sup>59,64</sup> with infusion via the right hepatic artery separated by 4 weeks from infusion via the left hepatic artery, if a whole liver treatment is needed.

Kennedy et al studied the incidence of RILD after 680 SIRT with resin microspheres. RILD was observed after 28 treatments (4%). Their data suggest an association between the activity delivered to the patient and RILD.<sup>65</sup> There may also be an association between the use of the empiric method for the calculation of the dose (for resin spheres) and toxicity.<sup>47</sup>

Prophylactic administration of corticosteroid, ursodeoxycholic acid being an antioxidant and antiapoptotic agent, low-molecular-weight heparin, glutamine infusion, prostaglandin-E<sub>1</sub>, pentoxifylline, and defibrotide which is a polydeoxyribonucleotide that has been found to have antithrombotic, anti-ischemic, and thrombolytic properties without causing significant anticoagulation, may be of benefit.<sup>66-68</sup>

High doses of corticosteroids are traditionally administered in an attempt to decrease intrahepatic inflammation. Treatment results are variable and mostly nongratifying, as the condition progresses in some patients to hepatic insufficiency of various degrees.<sup>8</sup>

In most patients, the only treatment needed is the use of diuretics and sodium restriction to maintain water and sodium balance. Hepatotoxic drugs should be avoided and infections should be identified and treated promptly.

In our department, all patients undergoing whole liver treatment in 1 therapy session receive prophylactic ursodeoxycholic acid, 600 mg/d for 1 month along with low-dose prednisolone (10 mg/d, reduction to 5 mg/d after 4 weeks) for 2 months. The liver function tests will be monitored every 2 weeks and cortisone could be tapered if there are no signs of RILD.

**Bile Duct Complications.** Both intra- and extrahepatic biliary complications following SIRT administration are due to the embolic and radiation-induced necrosis of the biliary ducts. The incidence of biliary sequelae is less than 10%.<sup>47</sup> Biliary injury may take the form of biloma formation, bile duct strictures and dilations, biliary cysts, cholangitis, cholecystitis, and gallbladder infarction.<sup>69</sup>

**Radiation-induced Cholecystitis.** The gallbladder also may receive radioactive microspheres through a patent cystic artery; a characteristic thick-walled appearance of the gallbladder is observed on cross-sectional images in such cases. To avoid this complication, infusion distal to the cystic artery is preferred; however, the risk of cholecystitis requiring cholecystectomy is low.<sup>34,70,71</sup>

**Figure 3** Therapy control with  $^{18}\text{F}$  fluorodeoxyglucose positron emission tomography in a patient with CRC. Whole-body maximum intensity projection view performed before (A) and 4 weeks after whole liver selective internal radiation therapy (SIRT) (B) with complete metabolic remission of the liver metastases. The white arrow indicates 2 lymph node metastases unchanged by the procedure.

## Follow-up

Definitions of the appropriate length of follow-up and the time points required for technical success are not well-established, and follow-up schedules after treatment vary depending on the treatment plan of each patient.

Continued monitoring of liver function tests is recommended to determine the outcome of treatment. This includes monitoring for stabilization in liver function tests due to the control of disease.<sup>11</sup> A biweekly assessment to rule out RILD is recommendable in the first 2 months after SIRT.

Abdominal and whole-body imaging should be performed for evaluation of response and evaluation of extrahepatic metastases with a sequence that differs according to tumor type and individual treatment plan. In our department, patients receive the first imaging consisting of abdomen MRI and a metabolic imaging, normally PET/CT, 4 weeks after therapy. The next series of imaging are performed 3, 6, 9, and 12 months after therapy, unless there are other reasons for further imaging studies, such as disease progression or performing other therapies like chemotherapy.

## Response Evaluation

The RECIST (Response Evaluation Criteria in Solid Tumors) method<sup>72,73</sup> defines standard measurement methods for converting visual image observations into a quantitative and statistically tractable framework for measuring tumor size response to therapy measured by MRI, CT, or ultrasound.<sup>74,75</sup> The results of measurements are subsequently assigned to response-defined categories of complete response (CR), partial response (PR), stable disease (SD), and progressive disease (PD), which mean disappearance of all target lesions, 30% decrease in the sum of the longest diameter of target lesions, small changes that do not meet the above criteria, and 20% increase in the sum of the longest diameter of target lesions, respectively.<sup>74</sup> Tumor size, however, does not necessarily reflect the number of viable tumor cells. As a result, the classical approach of assessing response by measurement of tumor size may be of value only months after therapy.<sup>76</sup> On the other hand, disagreement among observers has been noted to be as high as 15%-40%.<sup>77</sup>

The most common change in the CT-appearance of the liver after SIRT is decreased attenuation in the affected hepatic areas. This and other physiological changes are thought to represent liver edema, congestion, and microinfarction. Changes are more noticeable on the scans obtained soon after therapy than on those obtained later, a fact that suggests that such changes are reversible.<sup>8</sup> On scans of 90Y-treated livers that received an absorbed radiation dose of 100 Gy or less, the low-attenuation areas are heterogeneous. However, on scans of livers that received a dose of 125 Gy or more, the changes are diffuse. These changes have been seen at 8 weeks after radiation therapy and were diminished at 16-week follow-up.<sup>78</sup> It is of great importance that these changes are not to be mistaken with the evidence of recurrent disease.

Since PET has the ability to give information about the metabolic activity of a particular tissue, it has great potential to predict the response to systemic chemotherapy or regional therapy earlier than morphological imaging methods, which require evidence of morphological changes that may take some weeks.<sup>79</sup> In case of a significant difference between the metabolic response assessed by FDG-PET and the morphologic response assessed by CT after SIRT, metabolism is found to be a more sensitive and accurate indicator of treatment response (Fig. 3).<sup>80-83</sup> The total standard uptake value of the entire axial slices of the liver as well as of the individual lesion correlated well with subjective and visual evaluations.<sup>84</sup>

Survival time after SIRT is usually determined by the development of extrahepatic disease. The combination of morphologic and functional imaging shows the highest sensitivity for identifying this situation. Early diagnosis is important for potential additional salvage chemotherapy, radiation, or perhaps a repeated SIRT.

There are general limitations of PET techniques, including limited spatial resolution, scatter and attenuation, and other issues frequently confronting clinicians when acquiring pre- and post-therapeutic images for SIRT. Thus, the optimal therapy controlling may be performed by using PET/CT and MRI together.<sup>85</sup> Both modalities have particular diagnostic

**Table 4** Summarized Results of SIRT in Various Settings of Hepatic Metastasized CRC

Study	n	Setting	Treatment	Design	Response ORR	Survival TTP (mo)	Survival OS (mo)*
Gray et al (2000) <sup>86</sup>	71	Mixed	Resin + HAC FUDR	RS	55% (89% CEA)	NA	13.5 (EHD: 9.9)
Gray et al (2001) <sup>87</sup>	74	1st line <sup>†</sup>	HAC FUDR +/- resin	RCT phase 3	44% vs 17.6%	15.9 <sup>‡</sup> vs 9.7 <sup>‡</sup>	17 vs 15.9
Van Hazel et al (2004) <sup>89</sup>	21	1st line	5-FU/LV +/- resin	RCT phase 2	91% vs 0%	18.6 vs 3.6	29.4 vs 14.1
Sharma et al (2007) <sup>93</sup>	20	1st line	FOLFOX4 + resin	PS phase 1	90%	9.3 (12.3) <sup>‡</sup>	NA
Van Hazel et al (2005) <sup>94</sup>	25	2nd line 36% >2nd	Irinotecan + resin	PS phase 1	47%, SD 37%	6 (7) <sup>‡</sup>	12
Lewandowski et al (2005) <sup>18</sup>	27	Salvage ≥2nd line	Glass	PS phase 2	35%, SD 52%	NA	9.3 (95% CI 7.2-13.3)
Sato et al (2008) <sup>90</sup>	51	Salvage	Glass	PS phase 2	NA	NA	15.2
Kennedy et al (2006) <sup>43</sup>	208	Salvage	Resin	RS	35% (85%), <sup>§</sup> SD 55%	NA	10.5 <sup>¶</sup>
Stubbs (2006) <sup>95</sup>	100	Mixed (1st line)	Resin + HAC 5-FU <sup>  </sup>	RS	(74%), <sup>#</sup> SD 20%	NA	11
Mancini et al (2006) <sup>92</sup>	35	Salvage ≥3rd line	Resin	PS, MCT phase 2	12.5%, SD 75%	NA	NA
Cosimelli et al (2008) <sup>91</sup>	50	Salvage	Resin	PS, MCT phase 2	24%, SD 24%	4	13 (95% CI 7-18)
Mulcahy et al (2009) <sup>8</sup>	72	Mixed** 39% ≥3rd	Glass	PS	40% (77%), <sup>§</sup> SD 44.5%	15.4 <sup>‡</sup>	14.5

ORR, overall response rate; TTP, time-to-progression; OS, overall survival; RCT, randomized controlled study; RS, retrospective study; PS, prospective study; MCT, multicenter trial; NA, not available; HAC, hepatic artery chemotherapy; EHD, extrahepatic disease.

\*Median OS from start of treatment.

<sup>†</sup>n = 64 (10 pts > 1st line).

<sup>‡</sup>Hepatic TTP.

<sup>§</sup>FDG PET.

<sup>¶</sup>In responders.

<sup>||</sup>n = 80 with subsequent HAC.

<sup>#</sup>Size reduction.

\*\*39% ≥3rd line (n = 28 pts).

strengths and weaknesses, whereas PET-CT is superior in lymph node detection, and the assessment of tumor viability after regional therapy, high-resolution MRI using parallel acquisition techniques represent a promising alternative particularly in the staging of tumors with known poor FDG uptake, such as renal cell carcinoma or HCC.<sup>27</sup>

## Clinical Results of the SIRT in Primary and Secondary Liver Malignancies

### SIRT for the Liver Metastases of Colorectal Cancer

Gray et al<sup>86</sup> showed in a group of 71 consecutive patients with advanced liver metastases from colorectal cancer (CRC) who were treated with 1 or 2 injections of SIR-spheres followed by hepatic HAC and an objective response rate of 89% (PR + CR) when measured by CEA. Eighty-six percent of patients in this study experienced a decrease in tumor volume. Mean and median survival for patients with metastases confined to the liver was 14.5 and 13.5 months from the time of SIRT. A total of 74 patients with bilobar nonresectable liver metastases from CRC entered a phase III randomized clinical trial.<sup>87</sup> This trial was designed to measure any increased patient benefit by adding a single administration of SIR-spheres to a regimen of regional hepatic artery chemotherapy administered as a 12-day infusion of floxuridine and repeated at monthly intervals (36 patients), vs the same chemotherapy alone. The partial and CR rate was significantly greater for patients receiving SIR-spheres when measured by tumor areas (44% vs 17.6%,  $P = 0.01$ ), tumor volumes (50% vs 24%,  $P = 0.03$ ), and CEA (72% vs 47%,  $P = 0.004$ ). The median time to disease progression in the liver was significantly

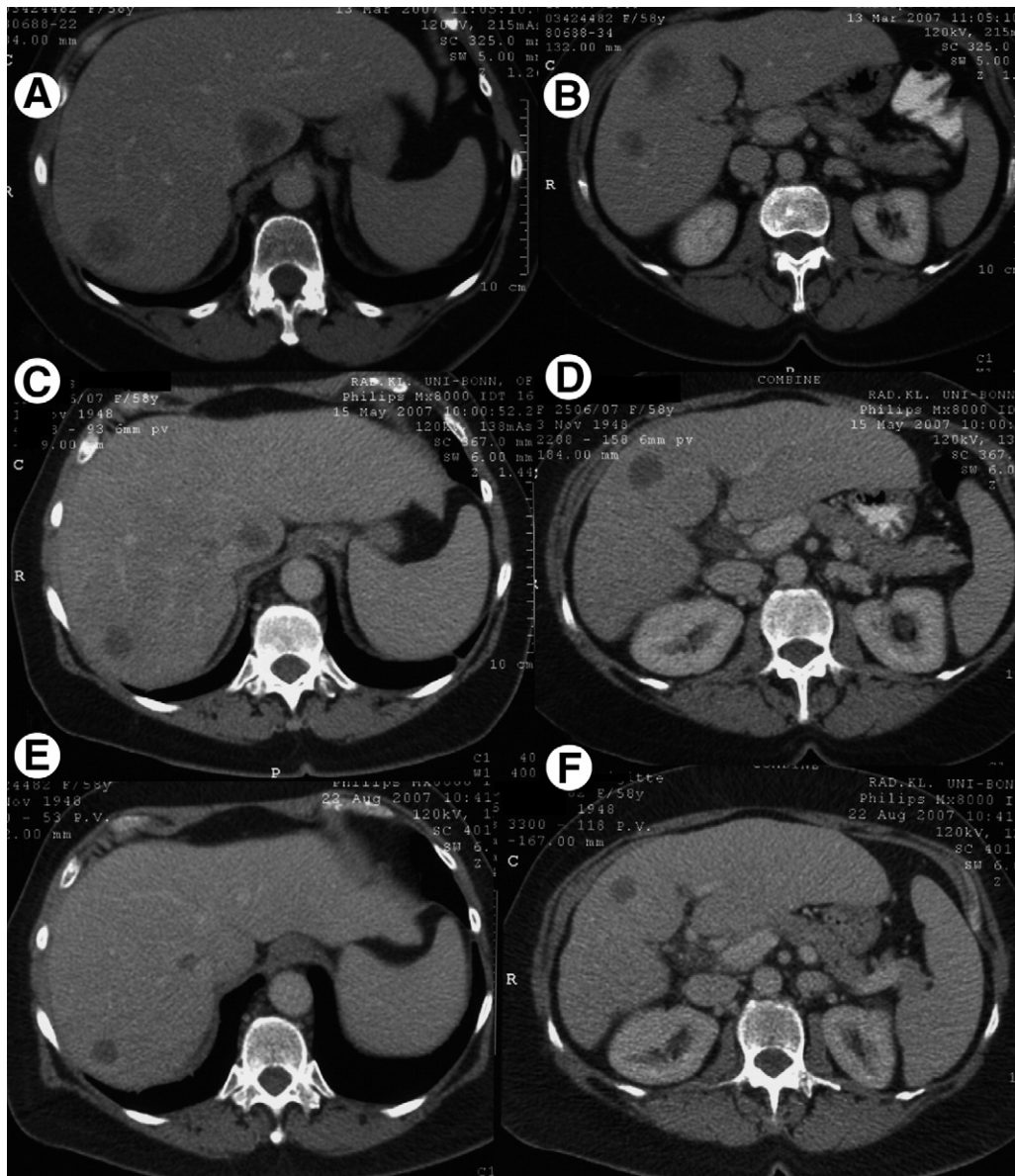
longer for patients receiving SIR-spheres in comparison with patients receiving HAC alone, when measured by either tumor areas (9.7 vs 15.9 months,  $P = 0.001$ ), tumor volumes (7.6 vs 12.0 months,  $P = 0.04$ ), or CEA (5.7 vs 6.7 months,  $P = 0.06$ ). In this study, 31 patients received SIR-spheres as a first-line therapy. They conclude that the combination of a single injection of SIRTex and HAC is substantially more effective in increasing tumor responses and progression-free survival than the same regimen of HAC alone.

Stubs et al,<sup>88</sup> in a study of 100 patients treated with SIR-spheres followed by HAC with 5-FU, showed 94% tumor response in 3 months and 74% in 6 months after therapy.

In a randomized trial, Van Hazel et al<sup>89</sup> compare the response rate and time to progression disease in a regimen of systemic fluorouracil/leucovorin chemotherapy vs the same chemotherapy along with a single administration of SIR-spheres in patients with advanced colorectal liver metastases. The time to PD and median survival were significantly longer for patients receiving the combination treatment. In some publications, the benefit of SIRT as salvage therapy have been shown with up to 85% PR + SD treated with resin or glass microspheres.<sup>4,18,43,88,90-92</sup> In Table 4, the results of SIRT as first-line, second-line, and salvage therapy in patients with hepatic metastases of CRC were summarized (Fig. 4).

### SIRT for the Liver Metastases of HCC

Geschwind et al<sup>97</sup> published a comprehensive analysis on using Therasphere for HCC, which showed improved survival in Okuda I compared with Okuda II.<sup>96</sup> In this study, patients classified as Okuda stage I (n = 54) and II (n = 26) had median survival durations and 1-year survival rates of 628 days and 63%, and 384 days and 51%, respectively ( $P = 0.02$ ).<sup>97</sup>



**Figure 4** Therapy control with CT in a patient with hepatic metastases of CRC before, 2 and 5 months after whole liver SIRT depicting a clear response that was accompanied by normalization of tumor markers. (A, C) Coronal CT before SIRT. (B, D) Coronal CT 2 months after SIRT, (E, F) coronal CT 5 months after SIRT.

In a recent published prospective study, 291 patients were administered 526 treatments with Therasphere. Response rates were 42% and 57% based on WHO and EASL criteria, respectively. The overall time to progression was 7.9 months. Survival times differed between Child-Pugh A and B patients (A: 17.2 month, B: 7.7 month,  $P = 0.002$ ). Child-Pugh B patients with PVT survived 5.6 months (95% CI: 4.5-6.7). They showed that Child-Pugh A patients, with or without PVT, benefited most from the treatment. Child-Pugh B patients with PVT had poor outcomes.<sup>98</sup>

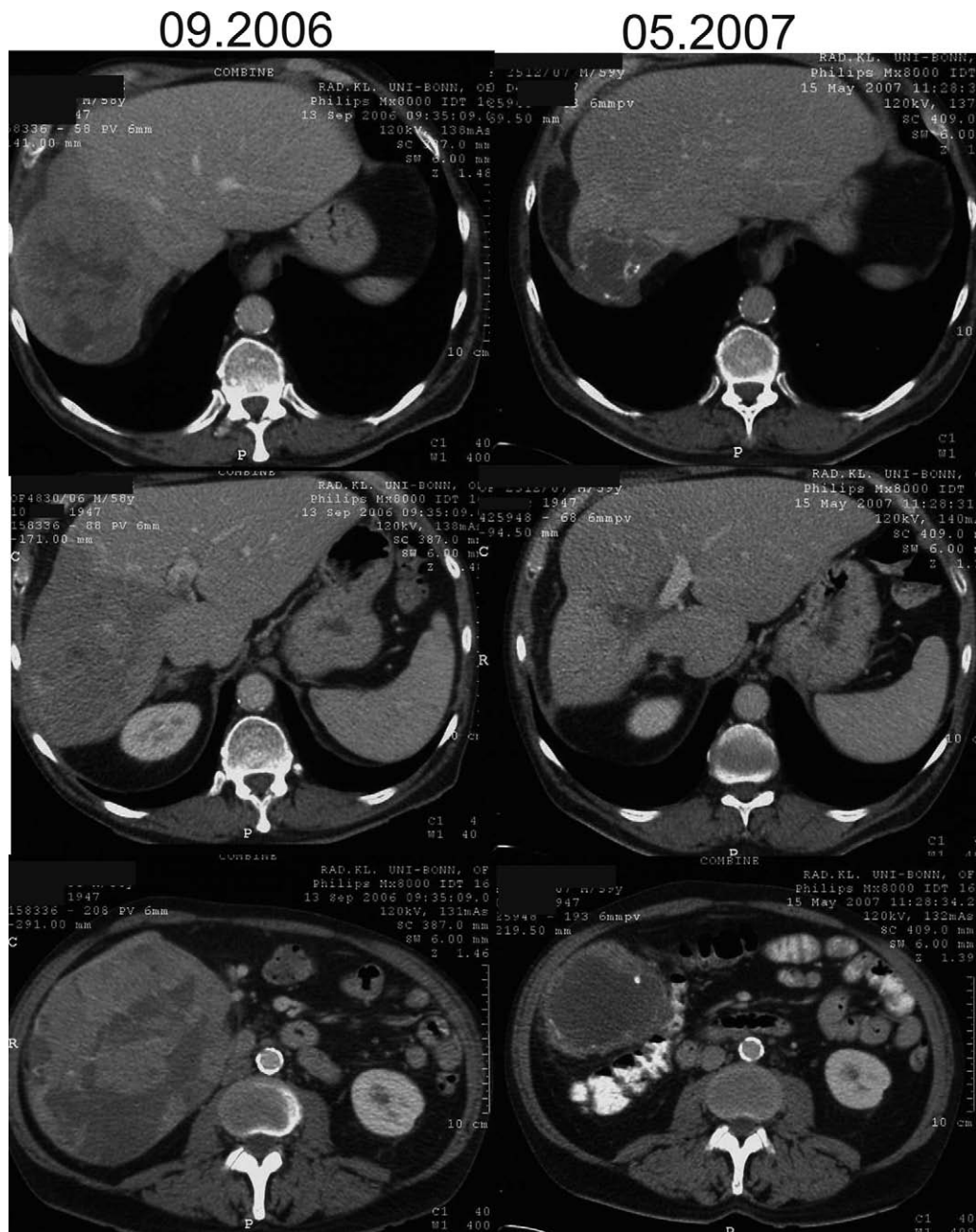In a meta-analysis of 14 recently published articles by Venti et al,<sup>55</sup> showed almost 80% any response (AR = [CR + PR + SD]) for a total of 325 patients with HCC. This meta-analysis treatment with resin microspheres was associated with a significantly higher proportion of AR than glass microsphere treat-

ment (0.89 vs 0.78 [ $P = 0.02$ ]). Median survival from RE varied between 7.1 and 21.0 months, and median survival from diagnosis or recurrence was 9.4-24.0 months (Fig. 5).

Kulik et al<sup>99</sup> in a study on 35 patients with T3 unresectable HCC who were treated with SIRT with the specific intent of downstaging to resection, RFA. They showed that SIRT can be used as a bridge to transplantation, surgical resection, or RFA. This allows the patients more time to wait for donor organs and thus increase their chance to undergoing liver transplantation.<sup>96</sup>

### SIRT for the Liver Metastases of Other Origins

There are some other trials considering SIRT for liver metastases of tumors such as NET, CCC, or breast cancer.



**Figure 5** Remission of a large unifocal hepatocellular carcinoma, involving the complete right liver lobe and extending into the pelvis. Major shrinkage is seen at restaging with CT 8 months after lobar radioembolization (right). Alpha-fetoprotein levels normalized from initial values of >3000. The patient presents in remission after >2 years at latest follow-up.

NET comprise approximately 10% of all metastatic liver lesions.<sup>100</sup> Rhee et al<sup>101</sup> in a study with 42 patients who underwent SIRT using glass or resin microspheres demonstrated 92% of glass and 94% of resin patients were classified as PR or SD at 6 months after treatment.

In a multicenter study of Kennedy et al,<sup>102</sup> 148 patients were treated with 185 separate procedures. Imaging response was stable in 22.7%, PR in 60.5%, CR in 2.7%, and PD in 4.9%. No radiation liver failure occurred. The median survival was 70 months.

King et al<sup>103</sup> treated 34 patients who had unresectable NET. Symptomatic responses were observed in 18 of 33 pa-

tients (55%) at 3 months and in 16 of 32 patients (50%) at 6 months. Radiological liver responses were observed in 50% of patients and included 6 (18%) CR and 11 (32%) PR, and the mean overall survival was  $29.4 \pm 3.4$  months. In patients who had evaluable CgA marker levels, there was a decrease in CgA marker levels after RE.

In a recent published study, Kalinowski et al<sup>104</sup> enrolled 9 patients with NET in a prospective trial. The mean tumor load was 58.8%. A total of 12 therapy sessions were performed. The mean follow-up was 21.7 months. Technical success was 100%. No major complications occurred. Survival rates were 100%, 57%, and 57% for 1, 2, and 3 years,

**Table 5** Summarized Results of SIRT in Patients With NET, Breast Cancer, CCC, and Ocular Melanoma

Study	n	Tumor	Treatment	Design	Response ORR	Survival TTP (mo)	Survival OS (mo)*
Rhee et al (2008) <sup>101</sup>	42	NET	Glass or resin	PS, MCT phase 2	51.7%, SD 41.4%	NA	25 (22 G, 28 R)
Kennedy et al (2008) <sup>102</sup>	148	NET	Resin	RS, MCS	63.2% (SD 22.7)	NA	70
King et al (2008) <sup>103</sup>	34	NET	Resin + 5FU <sup>†</sup>	PS	50%	NA	27.6
Kalinowski et al (2009) <sup>104</sup>	9	NET	Resin	PS	67% (SD 33%)	11.1	>36
Jacobs et al (2008) <sup>105</sup>	30	Breast cancer	Resin	RS	61% (SD 35%)		11.7
Coldwell et al (2007) <sup>106</sup>	44	Breast cancer	Resin	RS	47% PET: 95%	NA	Not reached <sup>‡</sup> >14
Ibrahim et al (2008) <sup>107</sup>	24	ICC	Glass	RS	27% EASL: 77%	NA	14.9
Coldwell et al (2007) <sup>106</sup>	23	ICC >3rd line <sup>†</sup>	Resin	RS	45% PET: 90%	NA	NA
Kennedy et al (2009) <sup>60</sup>	11	Ocular melanoma	Resin	RS	PET: 100%	NA	>30 (median OS not yet reached)

ICC, intrahepatic cholangiocarcinoma.

\*Median OS from start of treatment.

<sup>†</sup>Concomitant intravenous 5-FU over 1 week.

<sup>‡</sup>86% pts alive after 14 months follow-up.

respectively. Three months after SIRT therapy, PR was seen in 6 patients (66%). Calculated reduction of liver metastasis volume was 49%. In 3 patients (33%), SD was seen with a calculated tumor reduction of 13%. The estimated time to progression was 11.1 months (Table 5).

The percentage of patients with breast cancer who will eventually develop metastatic disease in the liver is less known, but is believed to be at least 60%.<sup>108</sup>

In a study with 30 patients who underwent SIRT with resin microspheres in a single-session, whole-liver treatment follow-up at a median of 4.2 months demonstrated PR, SD, and PD in 61%, 35%, and 4% of patients, respectively. With respect to tumor diameters, imaging revealed a maximum and minimum response of -64.8% to +23.6%, respectively. The median overall survival was 11.7 months. The median survival of responders and nonresponders was 23.6 and 5.7 months, respectively, and the median survival of patients with and without extrahepatic disease was 9.6 and 16 months, respectively.<sup>105</sup>

In a study from Coldwell et al, a total of 44 women who were treated with resin microspheres demonstrated a computed tomographic imaging PR by 47% and positron emission tomographic response 95% (Table 5).<sup>106</sup>

Ibrahim et al<sup>107</sup> performed 48 SIRT in 24 patients with CCC. On imaging follow-up of 22 patients, tumors demonstrated a PR in 6 patients (27%), SD in 15 patients (68%), and PD in 1 patient (5%). By using EASL guidelines, 17 patients (77%) showed >50% tumor necrosis on imaging follow-up. Two patients (9%) demonstrated 100% tumor necrosis. The median overall survival for the entire cohort was 14.9 months.

In a recent published study with a small group of patients with hepatic metastases of ocular melanoma, Kennedy et al showed the benefit of SIRT considering the control of hepatic metastases with very few side effects. In this study, 11 pa-

tients received 12 treatments with a median activity of 1.55 GBq delivered per treatment. Toxicity was minimal, with PET/CT at 3 months post-treatment showing a response in all patients; 1 patient had CR.<sup>60</sup>

## Conclusion

SIRT is a powerful tool to achieve regional tumor response and disease control in hepatic malignancy of various origins. Otherwise, treatment refractory tumors will frequently respond to this potent therapeutic modality due to the extraordinary local radiation doses achieved. Caution regarding patient selection, treatment preparation, and performance is particularly important to prevent serious toxicity to be associated with this highly efficacious treatment. Improvements in predicting dosimetry will lead to optimization of treatment outcome even in borderline treatment candidates. With the sustained accumulation of promising clinical results, SIRT is moving forward from the salvage setting indication to the use in earlier stages of hepatic tumor disease. Large prospective studies will help define the role of SIRT in metastatic and primary liver cancer disease. Embedding SIRT into a multidisciplinary approach will become even more important with the advent of new treatment protocols and targeted therapies. The interdisciplinary aspect of patient management has to be emphasized for this particular treatment form.

## References

1. Salem R, Thurston KG: Radioembolization with <sup>90</sup>Yttrium microspheres: A state-of-the-art brachytherapy treatment for primary and secondary liver malignancies. Part 1: Technical and methodologic considerations. *J Vasc Interv Radiol* 17:1251-1278, 2006
2. Abdalla EK, Vauthey JN, Ellis LM, et al: Recurrence and outcomes following hepatic resection, radiofrequency ablation, and combined

- resection/ablation for colorectal liver metastases. *Ann Surg* 239:818-825, 2004; discussion 825-827
3. Jarnagin WR, Gonen M, Fong Y, et al: Improvement in perioperative outcome after hepatic resection: Analysis of 1,803 consecutive cases over the past decade. *Ann Surg* 236:397-406, 2002; discussion 406-397
  4. Mulcahy MF, Lewandowski RJ, Ibrahim SM, et al: Radioembolization of colorectal hepatic metastases using yttrium-90 microspheres. *Cancer* 115:1849-1858, 2009
  5. Kennedy A, Nag S, Salem R, et al: Recommendations for radioembolization of hepatic malignancies using yttrium-90 microsphere brachytherapy: A consensus panel report from the radioembolization brachytherapy oncology consortium. *Int J Radiat Oncol Biol Phys* 68:13-23, 2007
  6. Dawson LA, Normolle D, Balter JM, et al: Analysis of radiation-induced liver disease using the Lyman NTCP model. *Int J Radiat Oncol Biol Phys* 53:810-821, 2002
  7. Greco C, Catalano G, Di Grazia A, et al: Radiotherapy of liver malignancies. From whole liver irradiation to stereotactic hypofractionated radiotherapy. *Tumori* 90:73-79, 2004
  8. Murthy R, Nunez R, Szklaruk J, et al: Yttrium-90 microsphere therapy for hepatic malignancy: Devices, indications, technical considerations, and potential complications. *Radiographics* 25(suppl 1):S41-S55, 2005
  9. Campbell AM, Bailey IH, Burton MA: Analysis of the distribution of intra-arterial microspheres in human liver following hepatic yttrium-90 microsphere therapy. *Phys Med Biol* 45:1023-1033, 2000
  10. Lien WM, Ackerman NB: The blood supply of experimental liver metastases. II. A microcirculatory study of the normal and tumor vessels of the liver with the use of perfused silicone rubber. *Surgery* 68:334-340, 1970
  11. Sirtex Medical Limited. Sirtex medical training manual, training program physicians and institutions. Australia. Available at: [http://www.sirtex.com/usa/\\_data/page/549/TRN-US-0320for20US1.pdf](http://www.sirtex.com/usa/_data/page/549/TRN-US-0320for20US1.pdf). Accessed October 16, 2007
  12. Sarfaraz M, Kennedy AS, Lodge MA, et al: Radiation absorbed dose distribution in a patient treated with yttrium-90 microspheres for hepatocellular carcinoma. *Med Phys* 31:2449-2453, 2004
  13. Sarfaraz M, Kennedy AS, Cao ZJ, et al: Physical aspects of yttrium-90 microsphere therapy for nonresectable hepatic tumors. *Med Phys* 30:199-203, 2003
  14. Dancey JE, Shepherd FA, Paul K, et al: Treatment of nonresectable hepatocellular carcinoma with intrahepatic 90Y-microspheres. *J Nucl Med* 41:1673-1681, 2000
  15. Stubbs RS, Cannan RJ, Mitchell AW: Selective internal radiation therapy (SIRT) with 90Yttrium microspheres for extensive colorectal liver metastases. *Hepatogastroenterology* 48:333-337, 2001
  16. Lawrence TS, Robertson JM, Anscher MS, et al: Hepatic toxicity resulting from cancer treatment. *Int J Radiat Oncol Biol Phys* 31:1237-1248, 1995
  17. Salem R, Lewandowski R, Roberts C, et al: Use of Yttrium-90 glass microspheres (TheraSphere) for the treatment of unresectable hepatocellular carcinoma in patients with portal vein thrombosis. *J Vasc Interv Radiol* 15:335-345, 2004
  18. Lewandowski RJ, Thurston KG, Goin JE, et al.: 90Y microsphere (TheraSphere) treatment for nonresectable colorectal cancer metastases of the liver: Response to treatment at targeted doses of 135-150 Gy as measured by [18F]fluorodeoxyglucose positron emission tomography and computed tomographic imaging. *J Vasc Interv Radiol* 16:1641-1651, 2005
  19. Salem R, Lewandowski RJ, Atassi B, et al: Treatment of unresectable hepatocellular carcinoma with use of 90Y microspheres (TheraSphere): Safety, tumor response, and survival. *J Vasc Interv Radiol* 16:1627-1639, 2005
  20. Delbeke D, Vitola JV, Sandler MP, et al: Staging recurrent metastatic colorectal carcinoma with PET. *J Nucl Med* 38:1196-1201, 1997
  21. Arulampalam TH, Francis DL, Visvikis D, et al: FDG-PET for the pre-operative evaluation of colorectal liver metastases. *Eur J Surg Oncol* 30:286-291, 2004
  22. Bohm B, Voth M, Geoghegan J, et al: Impact of positron emission tomography on strategy in liver resection for primary and secondary liver tumors. *J Cancer Res Clin Oncol* 130:266-272, 2004
  23. Ogunbiyi OA, Flanagan FL, Dehdashti F, et al: Detection of recurrent and metastatic colorectal cancer: Comparison of positron emission tomography and computed tomography. *Ann Surg Oncol* 4:613-620, 1997
  24. Herbertson RA, Scarsbrook AF, Lee ST, et al: Established, emerging and future roles of PET/CT in the management of colorectal cancer. *Clin Radiol* 64:225-237, 2009
  25. MacManus M, Nestle U, Rosenzweig KE, et al: Use of PET and PET/CT for radiation therapy planning: IAEA expert report 2006-2007. *Radiother Oncol* 91:85-94, 2009
  26. Yang M, Martin DR, Karabulut N, et al: Comparison of MR and PET imaging for the evaluation of liver metastases. *J Magn Reson Imaging* 17:343-349, 2003
  27. Jakobs T: Radiological detection and assessment of tumor response, in Bilbao JL, Reiser MF (eds): *Liver Radioembolization with 90Y Microspheres*. New York, NY, Springer, 2008, pp 93-106
  28. Roedl JB, Halpern EF, Colen RR, et al: Metabolic tumor width parameters as determined on PET/CT predict disease-free survival and treatment response in squamous cell carcinoma of the esophagus. *Mol Imaging Biol* 11:54-60, 2009
  29. Ramirez de Molina A, Rodriguez-Gonzalez A, Gutierrez R, et al: Overexpression of choline kinase is a frequent feature in human tumor-derived cell lines and in lung, prostate, and colorectal human cancers. *Biochem Biophys Res Commun* 296:580-583, 2002
  30. Hara T, Kosaka N, Kishi H: PET imaging of prostate cancer using carbon-11-choline. *J Nucl Med* 39:990-995, 1998
  31. Kwee SA, DeGrado TR, Talbot JN, et al: Cancer imaging with fluorine-18-labeled choline derivatives. *Semin Nucl Med* 37:420-428, 2007
  32. Talbot JN, Gutman F, Fartoux L, et al: PET/CT in patients with hepatocellular carcinoma using [(18)F]fluorocholine: Preliminary comparison with [(18)F]FDG PET/CT. *Eur J Nucl Med Mol Imaging* 33:1285-1289, 2006
  33. Yamamoto Y, Nishiyama Y, Kameyama R, et al: Detection of hepatocellular carcinoma using 11C-choline PET: Comparison with 18F-FDG PET. *J Nucl Med* 49:1245-1248, 2008
  34. Covey AM, Brody LA, Maluccio MA, et al: Variant hepatic arterial anatomy revisited: Digital subtraction angiography performed in 600 patients. *Radiology* 224:542-547, 2002
  35. Liu DM, Salem R, Bui JT, et al: Angiographic considerations in patients undergoing liver-directed therapy. *J Vasc Interv Radiol* 16:911-935, 2005
  36. Leung TW, Lau WY, Ho SK, et al: Radiation pneumonitis after selective internal radiation treatment with intraarterial 90yttrium-microspheres for inoperable hepatic tumors. *Int J Radiat Oncol Biol Phys* 33:919-924, 1995
  37. Lewandowski RJ, Sato KT, Atassi B, et al: Radioembolization with 90Y microspheres: Angiographic and technical considerations. *Cardiovasc Intervent Radiol* 30:571-592, 2007
  38. Ahmadzadehfah H, Sabet A, Biermann K, et al: The significance of Tc-99m-MAA SPECT-CT liver perfusion imaging in treatment planning for yttrium 90 microsphere selective internal radiation treatment [meeting abstracts 2]. *J Nucl Med* 50:1662, 2009
  39. Lau WY, Ho S, Leung TW, et al: Selective internal radiation therapy for nonresectable hepatocellular carcinoma with intraarterial infusion of 90yttrium microspheres. *Int J Radiat Oncol Biol Phys* 40:583-592, 1998
  40. TheraSphere Yttrium-90 Glass Microspheres Users Manual. MDS Nordion, Ottawa, Ontario, Canada
  41. Salem R, Hunter RD: Yttrium-90 microspheres for the treatment of hepatocellular carcinoma: A review. *Int J Radiat Oncol Biol Phys* 66(suppl 2):S83-S88, 2006
  42. Hamami ME, Poeppel TD, Muller S, et al: SPECT/CT with 99mTc-MAA in radioembolization with 90Y microspheres in patients with hepatocellular cancer. *J Nucl Med* 50:688-692, 2009

43. Kennedy AS, Coldwell D, Nutting C, et al: Resin 90Y-microsphere brachytherapy for unresectable colorectal liver metastases: Modern USA experience. *Int J Radiat Oncol Biol Phys* 65:412-425, 2006
44. Moroz P, Anderson JE, Van Hazel G, et al: Effect of selective internal radiation therapy and hepatic arterial chemotherapy on normal liver volume and spleen volume. *J Surg Oncol* 78:248-252, 2001
45. Lewandowski RJ, Salem R: Yttrium-90 radioembolization of hepatocellular carcinoma and metastatic disease to the liver. *Semin Intervent Radiol* 23:64-72, 2006
46. Murthy R, Habbu A, Salem R: Trans-arterial hepatic radioembolisation of yttrium-90 microspheres. *Biomed Imaging Interv J* 2:e43, 2006
47. Riaz A, Lewandowski RJ, Kulik LM, et al: Complications following radioembolization with yttrium-90 microspheres: A comprehensive literature review. *J Vasc Interv Radiol* 20:1121-1130, 2009
48. Fabbri C, Sarti G, Cremonesi M, et al: Quantitative analysis of 90Y Bremsstrahlung SPECT-CT images for application to 3D patient-specific dosimetry. *Cancer Biother Radiopharm* 24:145-154, 2009
49. Minarik D, Sjogreen Gleisner K, Ljungberg M: Evaluation of quantitative (90)Y SPECT based on experimental phantom studies. *Phys Med Biol* 53:5689-5703, 2008
50. Murthy R, Brown DB, Salem R, et al: Gastrointestinal complications associated with hepatic arterial yttrium-90 microsphere therapy. *J Vasc Interv Radiol* 18:553-562, 2007
51. Carretero C, Munoz-Navas M, Betes M, et al: Gastroduodenal injury after radioembolization of hepatic tumors. *Am J Gastroenterol* 102:1216-1220, 2007
52. Salem R, Parikh P, Atassi B, et al: Incidence of radiation pneumonitis after hepatic intra-arterial radiotherapy with yttrium-90 microspheres assuming uniform lung distribution. *Am J Clin Oncol* 31:431-438, 2008
53. Leung WT, Lau WY, Ho SK, et al: Measuring lung shunting in hepatocellular carcinoma with intrahepatic-arterial technetium-99m macroaggregated albumin. *J Nucl Med* 35:70-73, 1994
54. Yip D, Allen R, Ashton C, et al: Radiation-induced ulceration of the stomach secondary to hepatic embolization with radioactive yttrium microspheres in the treatment of metastatic colon cancer. *J Gastroenterol Hepatol* 19:347-349, 2004
55. Vente MA, Wondergem M, van der Tweel I, et al: Yttrium-90 microsphere radioembolization for the treatment of liver malignancies: A structured meta-analysis. *Eur Radiol* 19:951-959, 2009
56. Goin JE, Salem R, Carr BI, et al: Treatment of unresectable hepatocellular carcinoma with intrahepatic yttrium 90 microspheres: Factors associated with liver toxicities. *J Vasc Interv Radiol* 16(2 Pt. 1):205-213, 2005
57. Ingold JA, Reed GB, Kaplan HS, et al: Radiation hepatitis. *Am J Roentgenol Radium Ther Nucl Med* 93:200-208, 1965
58. Fox RA, Klemp PF, Egan G, et al: Dose distribution following selective internal radiation therapy. *Int J Radiat Oncol Biol Phys* 21:463-467, 1991
59. Sangro B, Bilbao JI, Boan J, et al: Radioembolization using 90Y-resin microspheres for patients with advanced hepatocellular carcinoma. *Int J Radiat Oncol Biol Phys* 66:792-800, 2006
60. Kennedy AS, Nutting C, Jakobs T, et al: A first report of radioembolization for hepatic metastases from ocular melanoma. *Cancer Invest* 27:682-690, 2009
61. Young JY, Rhee TK, Atassi B, et al: Radiation dose limits and liver toxicities resulting from multiple yttrium-90 radioembolization treatments for hepatocellular carcinoma. *J Vasc Interv Radiol* 18:1375-1382, 2007
62. Toohey RE, Stabin MG, Watson EE: The AAPM/RSNA physics tutorial for residents: Internal radiation dosimetry: Principles and applications. *Radiographics* 20:533-546, 2000; quiz 531-532
63. Goin JE, Salem R, Carr BI, et al: Treatment of unresectable hepatocellular carcinoma with intrahepatic yttrium 90 microspheres: A risk-stratification analysis. *J Vasc Interv Radiol* 16(2 Pt. 1):195-203, 2005
64. Hoffmann R, Bilbao JI, Jakobs T, et al: Complications and side effects, in Bilbao JI, Reiser MF (eds): *Liver Radioembolization with 90Y Microspheres*. New York, NY, Springer, 2008, pp 139-146
65. Kennedy AS, McNeillie P, Dezarn WA, et al: Treatment parameters and outcome in 680 treatments of internal radiation with resin 90Y-microspheres for unresectable hepatic tumors. *Int J Radiat Oncol Biol Phys* 74:1494-1500, 2009
66. Senzolo M, Germani G, Cholongitas E, et al: Venous occlusive disease: Update on clinical management. *World J Gastroenterol* 13:3918-3924, 2007
67. Bayraktar UD, Seren S, Bayraktar Y: Hepatic venous outflow obstruction: Three similar syndromes. *World J Gastroenterol* 13:1912-1927, 2007
68. Chopra R, Eaton JD, Grassi A, et al: Defibrotide for the treatment of hepatic veno-occlusive disease: Results of the European compassionate-use study. *Br J Haematol* 111:1122-1129, 2000
69. Atassi B, Bangash AK, Lewandowski RJ, et al: Biliary sequelae following radioembolization with Yttrium-90 microspheres. *J Vasc Interv Radiol* 19:691-697, 2008
70. Szyszko T, Al-Nahhas A, Tait P, et al: Management and prevention of adverse effects related to treatment of liver tumours with 90Y microspheres. *Nucl Med Commun* 28:21-24, 2007
71. Lewandowski RJ, Wang D, Gehl J, et al: A comparison of chemoembolization endpoints using angiographic versus transcatheter intraarterial perfusion/MR imaging monitoring. *J Vasc Interv Radiol* 18:1249-1257, 2007
72. Tran LN, Brown MS, Goldin JG, et al: Comparison of treatment response classifications between unidimensional, bidimensional, and volumetric measurements of metastatic lung lesions on chest computed tomography. *Acad Radiol* 11:1355-1360, 2004
73. Miller AB, Hoogstraten B, Staquet M, et al: Reporting results of cancer treatment. *Cancer* 47:207-214, 1981
74. Therasse P, Arbuck SG, Eisenhauer EA, et al: New guidelines to evaluate the response to treatment in solid tumors. European Organization for Research and Treatment of Cancer, National Cancer Institute of the United States, National Cancer Institute of Canada. *J Natl Cancer Inst* 92:205-216, 2000
75. Therasse P, Eisenhauer EA, Verweij J, et al: RECIST revisited: A review of validation studies on tumour assessment. *Eur J Cancer* 42:1031-1039, 2006
76. Wahl RL, Zasadny K, Helvie M, et al: Metabolic monitoring of breast cancer chemohormonotherapy using positron emission tomography: Initial evaluation. *J Clin Oncol* 11:2101-2111, 1993
77. Belton AL, Saini S, Liebermann K, et al: Tumour size measurement in an oncology clinical trial: Comparison between off-site and on-site measurements. *Clin Radiol* 58:311-314, 2003
78. Marn CS, Andrews JC, Francis IR, et al: Hepatic parenchymal changes after intraarterial Y-90 therapy: CT findings. *Radiology* 187:125-128, 1993
79. Tutt AN, Plunkett TA, Barrington SF, et al: The role of positron emission tomography in the management of colorectal cancer. *Colorectal Dis* 6:2-9, 2004
80. Bienert M, McCook B, Carr BI, et al: Sequential FDG PET/CT in 90Y microsphere treatment of unresectable colorectal liver metastases. *Eur J Nucl Med Mol Imaging* 32:723, 2005
81. Bienert M, McCook B, Carr BI, et al: 90Y microsphere treatment of unresectable liver metastases: Changes in 18F-FDG uptake and tumour size on PET/CT. *Eur J Nucl Med Mol Imaging* 32:778-787, 2005
82. Selzner M, Hany TF, Wildbrett P, et al: Does the novel PET/CT imaging modality impact on the treatment of patients with metastatic colorectal cancer of the liver? *Ann Surg* 240:1027-1034, 2004; discussion 1035-1036
83. Wong CY, Salem R, Raman S, et al: Evaluating 90Y-glass microsphere treatment response of unresectable colorectal liver metastases by [18F]FDG PET: A comparison with CT or MRI. *Eur J Nucl Med Mol Imaging* 29:815-820, 2002
84. Wong CY, Salem R, Qing F, et al: Metabolic response after intraarterial 90Y-glass microsphere treatment for colorectal liver metastases: Comparison of quantitative and visual analyses by 18F-FDG PET. *J Nucl Med* 45:1892-1897, 2004



85. Morikawa M, Demura Y, Ishizaki T, et al: The effectiveness of 18F-FDG PET/CT combined with STIR MRI for diagnosing nodal involvement in the thorax. *J Nucl Med* 50:81-87, 2009
86. Gray B, Van Hazel G, Buck M, et al: Treatment of colorectal liver metastases with SIR-Spheres plus chemotherapy. *GI Cancer* 3:249-257, 2000
87. Gray B, Van Hazel G, Hope M, et al: Randomised trial of SIR-Spheres plus chemotherapy vs. chemotherapy alone for treating patients with liver metastases from primary large bowel cancer. *Ann Oncol* 12:1711-1720, 2001
88. Stubbs RS, O'Brien I, Correia MM: Selective internal radiation therapy with 90Y microspheres for colorectal liver metastases: Single-centre experience with 100 patients. *ANZ J Surg* 76:696-703, 2006
89. Van Hazel G, Blackwell A, Anderson J, et al: Randomised phase 2 trial of SIR-Spheres plus fluorouracil/leucovorin chemotherapy versus fluorouracil/leucovorin chemotherapy alone in advanced colorectal cancer. *J Surg Oncol* 88:78-85, 2004
90. Sato KT, Lewandowski RJ, Mulcahy MF, et al: Unresectable chemorefractory liver metastases: radioembolization with 90Y microspheres—Safety, efficacy, and survival. *Radiology* 247:507-515, 2008
91. Cosimelli M, Mancini R, Carpanese L, et al: Clinical safety and efficacy of 90yttrium resin microspheres alone in unresectable, heavily pretreated colorectal liver metastases: Results of a phase II trial. In: Proceedings from the ASCO Annual Meeting; 2008; Chicago, IL
92. Mancini R, Carpanese L, Sciuto R, et al: A multicentric phase II clinical trial on intra-arterial hepatic radiotherapy with 90yttrium SIR-spheres in unresectable, colorectal liver metastases refractory to i.v. chemotherapy: Preliminary results on toxicity and response rates. *In Vivo* 20(6A):711-714, 2006
93. Sharma RA, Van Hazel GA, Morgan B, et al: Radioembolization of liver metastases from colorectal cancer using yttrium-90 microspheres with concomitant systemic oxaliplatin, fluorouracil, and leucovorin chemotherapy. *J Clin Oncol* 25:1099-1106, 2007
94. Van Hazel G, Pavlakis N, Goldstein D: Selective internal radiation therapy (SIRT) plus systemic chemotherapy with irinotecan. A phase I dose escalation study. In: Proceedings from the ASCO Annual Meeting. ASCO GI Symposium, Hollywood, FL; 2005 (abstract 265)
95. Stubbs RS: Portal hypertension and liver surgery following selective internal radiation therapy with 90Yttrium microspheres. *J Clin Oncol* 24:e15, 2006
96. Riaz A, Lewandowski RJ, Kulik L, et al: Yttrium-90 radioembolization using TheraSphere in the management of primary and secondary liver tumors. *Q J Nucl Med Mol Imaging* 53:311-316, 2009
97. Geschwind JF, Salem R, Carr BI, et al: Yttrium-90 microspheres for the treatment of hepatocellular carcinoma. *Gastroenterology* 127(5 suppl 1):S194-S205, 2004
98. Salem R, Lewandowski RJ, Mulcahy MF, et al: Radioembolization for hepatocellular carcinoma using Yttrium-90 microspheres: A comprehensive report of long-term outcomes. *Gastroenterology* (in press)
99. Kulik LM, Atassi B, van Holsbeeck L, et al: Yttrium-90 microspheres (TheraSphere) treatment of unresectable hepatocellular carcinoma: Downstaging to resection, RFA and bridge to transplantation. *J Surg Oncol* 94:572-586, 2006
100. Benevento A, Boni L, Frediani L, et al: Result of liver resection as treatment for metastases from noncolorectal cancer. *J Surg Oncol* 74:24-29, 2000
101. Rhee TK, Lewandowski RJ, Liu DM, et al: 90Y Radioembolization for metastatic neuroendocrine liver tumors: Preliminary results from a multi-institutional experience. *Ann Surg* 247:1029-1035, 2008
102. Kennedy AS, Dezarn WA, McNeillie P, et al: Radioembolization for unresectable neuroendocrine hepatic metastases using resin Y-90-microspheres: Early results in 148 patients. *Am J Clin Oncol Cancer Clin Trials* 31:271-279, 2008
103. King J, Quinn R, Glenn DM, et al: Radioembolization with selective internal radiation microspheres for neuroendocrine liver metastases. *Cancer* 113:921-929, 2008
104. Kalinowski M, Dressler M, Konig A, et al: Selective internal radiotherapy with Yttrium-90 microspheres for hepatic metastatic neuroendocrine tumors: A prospective single center study. *Digestion* 79:137-142, 2009
105. Jakobs TF, Hoffmann RT, Fischer T, et al: Radioembolization in patients with hepatic metastases from breast cancer. *J Vasc Interv Radiol* 19:683-690, 2008
106. Coldwell DM, Kennedy AS, Nutting CW: Use of yttrium-90 microspheres in the treatment of unresectable hepatic metastases from breast cancer. *Int J Radiat Oncol Biol Phys* 69:800-804, 2007
107. Ibrahim SM, Mulcahy MF, Lewandowski RJ, et al: Treatment of unresectable cholangiocarcinoma using yttrium-90 microspheres: Results from a pilot study. *Cancer* 113:2119-2128, 2008
108. Viadana E, Bross ID, Pickren JW: An autopsy study of some routes of dissemination of cancer of the breast. *Br J Cancer* 27:336-340, 1973