




Lyme Disease in a Women's Basketball Athlete

Karli Dill MA, ATC

Michael Huey MD




Patient



- 20 years old
- Female
- Vegetarian
- From New Hampshire
- No significant medical hx




Chief Complaints



- Fatigue
- Dizziness
- Myalgia
- Headache
- Fever
- Sore throat
- Achy joints
- Sleeping more than usual




Differential Diagnoses



- Upper respiratory infection
- Influenza
- Iron deficiency anemia
- Streptococcal Pharyngitis
- Mononucleosis
- Lyme Disease (region)




Sequence of Events



- Initial referral to SHS and nutrition
 - CBC, metabolic panel, sedimentation rate, rapid strep A, rapid mono
- Follow-up with head team physician
 - Enzyme-linked immunosorbent assay (ELISA), Epstein Barr virus panel, TSH




Sequence of Events



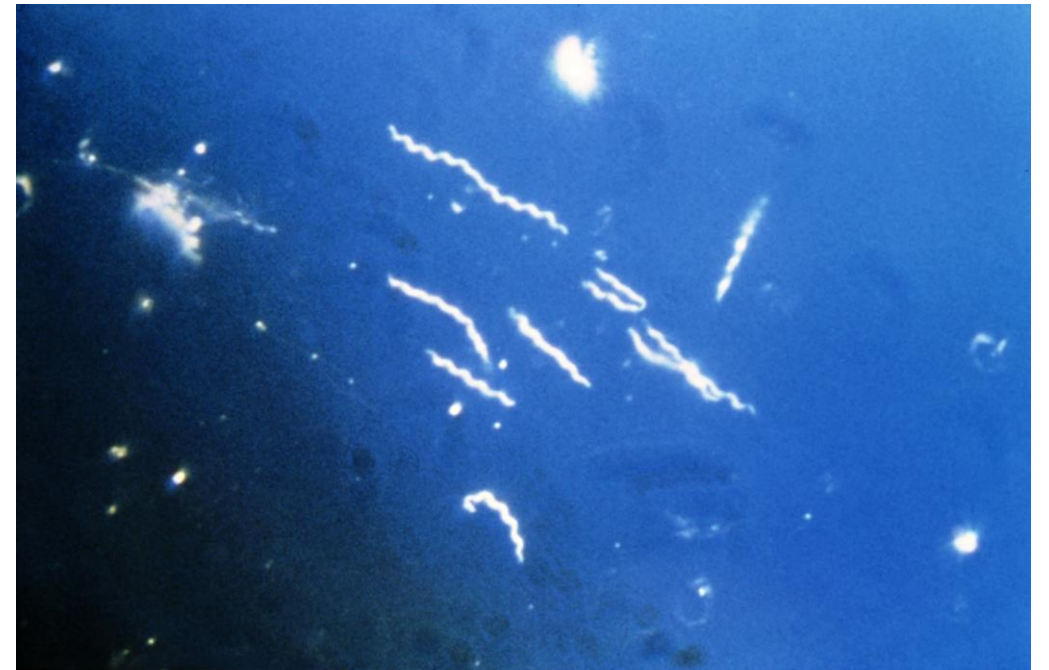- Referral to infectious disease
 - Borrelia burgdorferi
- Visit with Lyme disease specialist in NH
 - Repeat borrelia burgdorferi test sent to specialized lab with positive result



Diagnosis




- **Chronic Lyme Disease**
 - 300,000 cases each year in the US
 - 96% occur in the Northeast and northern Midwest regions
 - Can be a controversial diagnosis






Treatment



- Treatment consisted of oral antibiotics taken for 6 weeks beyond symptom resolution
 - Azithromycin & Cefuroxime




Sport Participation



- Limited activity due to symptoms of Lyme and/or side effects of antibiotics
- Changed course of treatment once symptoms diminished
 - Course of antibiotics for 1 week every month
- Able to participate the next season with minor difficulties from side effects
- Relapsed her senior year with less severe but consistent symptoms




Conclusion



- Important for ATC's to be aware of rare diseases
- Gather a thorough history and identify outliers
- Advocate for your patient!
- Every case is different!



References



Lyme Disease. (2019, December 16). Retrieved from <https://www.cdc.gov/lyme/>

Lyme disease: diagnosis and management. Ross-Russell AL, Dryden MS, Pinto AA, Lovett JK. Practical neurology. , 2018, Vol.18(6), p.455-464